



## Case report

## Unusual discovery: Incidental diagnosis of adrenal myelolipoma, initially confused with liposarcoma, following bee sting bite, resolving chronic right hypochondrial discomfort - A case report

Balasingam Balagobi<sup>a,\*</sup>, Sreekantham Gobishangar<sup>a</sup>, Jathavani Mariyo Maznet Theepan<sup>b</sup>, Kuganathan Priyatharsan<sup>a</sup>, Kanagalingam Heerthikan<sup>a</sup>, Thangarajah Vaishnavi<sup>a</sup>

<sup>a</sup> Department of Surgery, Faculty of Medicine, University of Jaffna, Sri Lanka

<sup>b</sup> Department of Pathology, Faculty of Medicine, University of Jaffna, Sri Lanka

## ARTICLE INFO

## Keywords:

Myelolipoma  
Incidentaloma  
Haematopoietic cell  
Adrenalectomy  
Adrenal mass

## ABSTRACT

**Introduction and importance:** Adrenal myelolipomas are uncommon benign tumors of the adrenal gland. It has various other sites of origin.

**Case presentation:** A 51-year-old male with elevated serum creatinine and an incidentally discovered adrenal mass underwent right adrenalectomy for an adrenal myelolipoma, a benign tumor with fat and haematopoietic components after bee sting bite. As the patient was experiencing right hypochondrial pain surgery was planned. After surgery, he developed a surgical site infection, which was treated with antibiotics, and his wound healed well. Excision biopsy confirmed the non-malignant nature of the tumor.

**Clinical discussion:** Adrenal myelolipomas are often unilateral, non-functional, and diagnosed using imaging (CT/MRI). While radiological findings can be specific, inconclusive cases may require biopsy for confirmation. Surgical intervention is reserved for hormonally active, symptomatic, or rapidly growing myelolipomas, particularly if they exceed 5 cm.

**Conclusion:** Adrenal myelolipomas are common in adrenal glands, typically diagnosed in midlife with no gender bias. Imaging, especially CT, is effective in detecting fat components. In cases of diagnostic uncertainty, fine needle biopsy is crucial for confirmation, and surgery is considered when tumors are hormonally active, grow substantially, or cause symptoms, highlighting personalized care based on patient and imaging data.

### 1. Introduction

Adrenal myelolipoma is an uncommon benign tumor of the adrenal gland [1]. Myelolipoma are usually of nonfunctional tissue and as its name indicates it contains various proportions of mature haematopoietic elements and adipose tissues [2]. Its common site of origin is the adrenal gland [1] but, other regions (extra-adrenal myelolipomas - EMLs) such as pre-sacral, retro-peritoneal, pelvic, liver, stomach, mesentery, lungs and mediastinal were also reported [3]. The incidence of myelolipomas seems to be rising from 0.2 % to 10 % during the last decade [4]. It is usually clinically silent [1] and considered as adrenal incidentaloma, which is defined as clinically unsuspected adrenal mass discovered on imaging studies conducted for reasons other than study of adrenal glands [5]. Symptoms tends to occur with rise in size of the lesion either due to mass effect or hemorrhage [6]. Symptoms varies

from non-specific abdominal pain, constipation, vomiting, to haematuria and renovascular hypertension. Acute hemorrhage within or from the tumor is a known serious complication.

Imaging used in adrenal myelolipoma are Ultrasound scan (US), Computed tomography (CT) and Magnetic Resonance imaging (MRI). Since myelolipomas contain different proportions of fat and myeloid tissue, a definitive diagnosis using only imaging with either Computed Tomography (CT) or Magnetic Resonance imaging (MRI) will be difficult in some circumstances. Image guided Fined Needle Aspiration Cytology (FNAC) can provide a diagnosis in most cases. Identification of mature adipose tissue intermixed with haematopoietic cells is diagnostic of myelolipoma in FNAC and excludes other malignant causes like well differentiated liposarcoma. As these tumors are nonfunctional endocrine tests are generally not useful and they are not recommended to be done routinely. This report was prepared based on the SCARE 2023 guideline

\* Corresponding author.

E-mail addresses: [b.balagobi@yahoo.com](mailto:b.balagobi@yahoo.com) (B. Balagobi), [sgobishangar@univ.jfn.ac.lk](mailto:sgobishangar@univ.jfn.ac.lk) (S. Gobishangar).

<https://doi.org/10.1016/j.ijscr.2023.109130>

Received 17 October 2023; Received in revised form 4 December 2023; Accepted 5 December 2023

Available online 11 December 2023

2210-2612/© 2023 The Authors. Published by Elsevier Ltd on behalf of IJS Publishing Group Ltd. This is an open access article under the CC BY-NC-ND license (<http://creativecommons.org/licenses/by-nc-nd/4.0/>).

[16].

## 2. Case presentation

A 51 year apparently well male patient was found to have elevated serum creatinine incidentally following admission due to bee sting bite. He hasn't previous comorbidities. His previous records revealed normal serum creatinine level and patient didn't have tachycardia, episodic sweating and headache. Subsequent US scan revealed an indeterminate supra renal mass. Investigations such cortisol level, plasma metanephrines, urine vanillylmandelic acid (VMA) results turned out to be normal. Contrast enhanced computerized tomography (CECT) abdomen revealed appearance is adrenal lesion with fat-containing components which is suggestive of adrenal myelolipoma (Fig. 1).

After identifying the mass, further discussion with patient, patient revealed a chronic right hypochondrial discomfort which was not previously evaluated. After undergoing pre-operative evaluation and optimization, he underwent right adrenalectomy and resection of the tumor by an experienced general surgeon and a genitourinary surgeon by open approach without any intra-operative complication (Fig. 2). He was discharged on post-operative day three without any immediate post-operative. Serum creatinine levels remained normal pre- and post-surgery. He got re-admitted again on post-operative day seven with purulent discharge from the incision site. He was then managed for surgical site infection which was negative for swab and pus cultures and had no intra-abdominal connection in ultrasound study. He had Clavian Dindo complication II. He was given intravenous antibiotics for a duration of five days according to the local protocol and discharged with completely healthy wound.

The histopathology report showed a specimen of enlarged adrenal gland weighing 280 g in the dimension of 145 × 110 × 80 mm with a tumor (11.3 × 10.0 × 9.6 cm) of yellow cut surface and fatty in consistency macroscopically. Microscopic section revealed a myelolipoma composed of mature adipocytes containing islands of haematopoietic cells (Fig. 3). The bone marrow component shows normal tri-lineage hematopoiesis. There were areas of cystic degeneration. The tumor reached the resection margins widely. Periphery of the tumor showed compressed unremarkable adrenal cortical tissue. There was no evidence of malignancy. Blood investigations were normal before and after surgery.

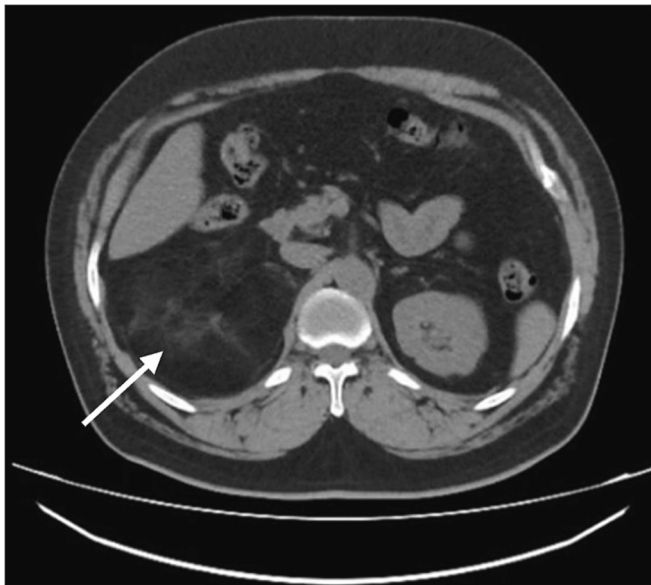


Fig. 1. Enhanced computed tomographic showing the lesion. (arrow indicates the lesion).

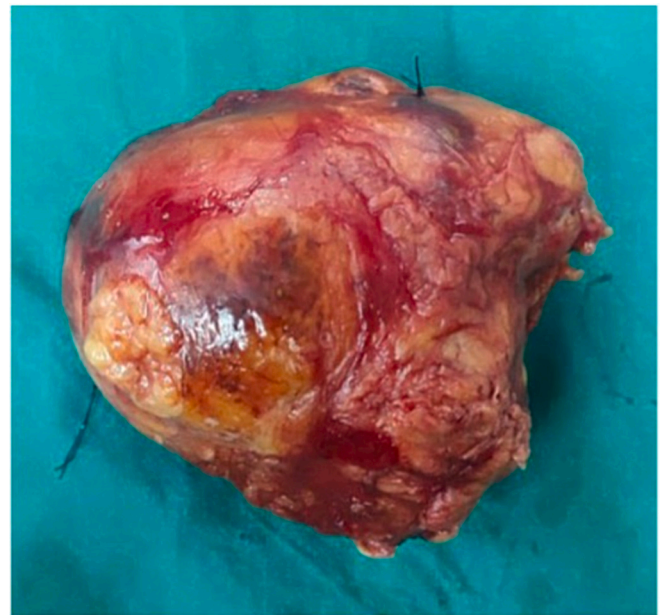


Fig. 2. Resected specimen from the right adrenalectomy, which had the dimension of 145 mm × 110 mm × 80 mm.

## 3. Discussion

Adrenal glands are the most common site of occurrence of myelolipomas [6]. Adrenal myelolipomas are usually unilateral, variable in size and the average age for diagnosis of myelolipoma is midlife, and no gender differences were observed [10,11]. The differential diagnosis included adrenal carcinoma or adenoma, metastatic carcinoma, lipoma or liposarcoma, angiomyolipoma of the kidney, and other granulomatous inflammation [2].

## 4. Diagnostic imaging and challenges

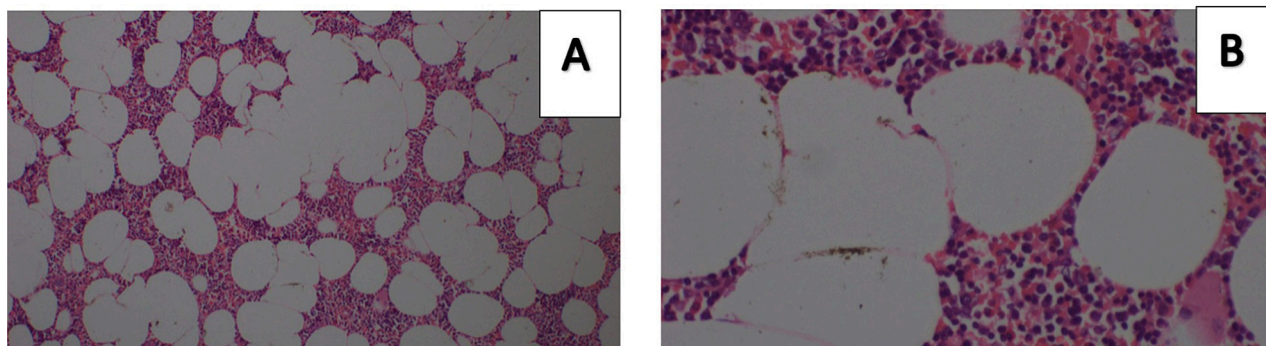
Ultrasonography, CT, and MRI are effective in diagnosing adrenal myelolipomas in >90 % of cases, with CT being the most sensitive diagnostic imaging modality. A fat containing components on CT virtually diagnostic of myelolipoma, although other less common adrenal tumors containing fat such as teratoma, lipoma and liposarcoma should be considered [12–14].

## 5. Management approaches

Standard management primarily revolves around vigilant observation, especially in cases of small, asymptomatic tumors. Surgical intervention might be considered in scenarios of considerable tumor size, symptomatic manifestations (Like pain/hormonal irregularities). Personalized guidance from a healthcare specialist is imperative to tailor recommendations based on individual circumstances.

Diagnosing adrenal myelolipoma typically doesn't involve assessing its hormonal activity, as it is generally considered non-functional [18]. If there are uncertainties in the radiographic diagnosis, indicating the possible presence of a different adrenal tumor alongside myelolipoma, or if clinical symptoms suggest the coexistence of an active adrenal tumor, it's advisable to conduct appropriate endocrine assessments [18].

In a study published in 2009, data from 196 consecutive adrenalectomies in 192 patients were studied and CT or MRI characteristics predicted the presence of benign lesions with 100 % specificity [7]. Even though the myelolipoma is a benign lesion as since it contains different proportions of fat and myeloid tissue a definitive diagnosis with just imaging such a CT or an MRI may be difficult in some instance especially



**Fig. 3.** Microscopic view showing adipose tissues intermixed with haematopoietic cells. A – X400 and B - X1000.

when only a small amount of fat is present. And presence of necrosis, hemorrhage and calcification is suspicious of malignancy, although they can occur in large adrenal myelolipoma [8].

There were also instances where radiologically diagnosed myelolipoma have been found pathologically to be different with malignant potential. In a case study which presented radiographic and pathologic features of three different patients with adrenocortical neoplasms; two patients had imaging finding compatible with adrenal myelolipoma and two of the lesions were classified as adrenocortical neoplasms of uncertain malignant potential in pathological diagnosis. All three lesions contained myelolipomatous foci throughout the neoplasm and two of the tumors contained several pure lipomatous foci. The author stated that imaging study may result in a false diagnosis of benign adrenal myelolipoma and potential under treatment in such patients [9].

Another study also suggested although myelolipomas have typical imaging features, these features may overlap with angiomyolipomas, lipomas, teratomas, and liposarcomas. Hence, the study suggested histopathologic examination as important for confirmation of diagnosis [15].

If the diagnosis of adrenal myelolipoma cannot be made with confidence using noninvasive imaging, fine needle biopsy should be considered to get a definitive diagnosis and in cases where expectant management is being considered to rule out malignancy [12]. If the diagnosis of an adrenal myelolipoma is unambiguous, and no associated symptoms or hormonal activity are established surgical intervention is usually not necessary [10].

## 6. Surgical intervention criteria and risk management

Surgical intervention is necessary in specific situations, such as when the tumors display hormonal activity, undergo growth in size, or lead to the onset of symptoms [19]. When managing small lesions measuring <5 cm in individuals without symptoms, it is common practice to conduct regular imaging assessments over a span of 1 to 2 years. However, based on findings from multiple studies, it is recommended that myelolipomas exceeding 5 cm in size or those causing symptoms should be considered for elective surgical removal [8,17,11]. Larger-sized adrenal myelolipomas carry an increased risk of urological emergencies, as reports have shown instances of spontaneous rupture and hemorrhage from the mass, leading to life-threatening cardiovascular shock [20]. In this case, surgery was performed due to the patient's prolonged experience of symptoms.

## 7. Conclusion

Adrenal myelolipomas commonly manifest in the adrenal glands, typically diagnosed around midlife without observed gender disparities. Diagnostic imaging methods like ultrasonography, CT, and MRI are highly effective, especially CT's sensitivity in identifying fat-containing elements characteristic of myelolipomas. However, there are scenarios

where imaging alone may not yield a conclusive diagnosis, warranting consideration for fine needle biopsy to confirm the absence of malignancy. Surgical intervention is selectively recommended for tumors displaying hormonal activity, substantial growth, or symptomatic expression. This underscores the necessity for an individualized approach, tailoring management to the unique characteristics of each patient and the findings from diagnostic imaging. The emphasis on personalized care based on patient-specific attributes remains pivotal in determining the most suitable course of action.

## Statement of informed consent

Written informed consent was obtained from the patient for publication of this case report and accompanying images. A copy of the written consent is available for review by the Editor-in Chief of this journal on request.

## Ethical approval

The ethics clearance was not necessary to this study because our Institutional Review Board (IRB) does not require ethical approval for reporting individual cases or case series.

## Funding

None.

## Author contribution

Study concept – Balagobi B and Gobishangar S.  
Data collection – Theepan J, Priyatharsan K, Heerthikan K, and Vaishnavi T.  
Data analysis – Priyatharsan K, Heerthikan K, and Vaishnavi T.

## Guarantor

Dr. Balasingham Balagobi.

## Conflict of interest statement

There is no conflict of interest between the authors as everybody is aware of the work and participated actively and equally.

## References

- [1] D. Dan, et al., Extra-adrenal perirenal myelolipoma. A case report and review of literature, *G. Chir.* 33 (3) (2012) 62–65.
- [2] J. Settakorn, et al., Fine-needle aspiration cytology of adrenal myelolipoma: case report and review of the literature, *Diagn. Cytopathol.* 21 (6) (1999) 409–412, [https://doi.org/10.1002/\(sici\)1097-0339\(199912\)21:6<409::aid-dc9>3.0.co;2-a](https://doi.org/10.1002/(sici)1097-0339(199912)21:6<409::aid-dc9>3.0.co;2-a).

- [3] R. Spanta, et al., Fine needle aspiration diagnosis of extraadrenal myelolipoma presenting as a pleural mass. A case report, *Acta Cytol.* 43 (2) (1999) 295–298, <https://doi.org/10.1159/000330997>.
- [4] S.I. Tyritzis, et al., Giant adrenal myelolipoma, a rare urological issue with increasing incidence: a case report, *Cases J.* 2 (2009) 8863, <https://doi.org/10.4076/1757-1626-2-8863>.
- [5] F. Paterson, et al., Radiology reporting of adrenal incidentalomas - who requires further testing? *Clin. Med. (Lond.)* 14 (1) (2014) 16–21, <https://doi.org/10.7861/clinmedicine.14-1-16>.
- [6] S. Sethi, et al., Myelolipoma of the pelvis: a case report and review of literature, *Front. Oncol.* 8 (2018) 251, <https://doi.org/10.3389/fonc.2018.00251>.
- [7] L. Yip, et al., The adrenal mass: correlation of histopathology with imaging, *Ann. Surg. Oncol.* 17 (3) (2010) 846–852, <https://doi.org/10.1245/s10434-009-0829-2>.
- [8] V.G. Shenoy, et al., Adrenal myelolipoma: controversies in its management, *Indian J. Urol.* 31 (2) (2015) 94–101, <https://doi.org/10.4103/0970-1591.152807>.
- [9] K.T. Montone, et al., Adrenocortical neoplasms with myelolipomatous and lipomatous metaplasia: report of 3 cases, *Endocr. Pract.* 15 (2) (2009) 128–133, <https://doi.org/10.4158/EP.15.2.128>.
- [10] Á. Decmann, P. Perge, M. Tóth, P. Igaz, Adrenal myelolipoma: a comprehensive review, *Endocrine* 59 (1) (2018 Jan) 7–15, <https://doi.org/10.1007/s12020-017-1473-4> (Epub 2017 Nov 21. PMID: 29164520).
- [11] J. Calissendorff, C.C. Juhlin, A. Sundin, I. Bancos, H. Falhammar, Adrenal myelolipomas, *Lancet Diabetes Endocrinol.* 9 (11) (2021 Nov) 767–775, [https://doi.org/10.1016/S2213-8587\(21\)00178-9](https://doi.org/10.1016/S2213-8587(21)00178-9) (Epub 2021 Aug 24. PMID: 34450092; PMCID: PMC8851410).
- [12] S. Daneshmand, M.L. Quek, Adrenal myelolipoma: diagnosis and management, *Urol. J.* 3 (2) (2006 Spring) 71–74 (PMID: 17590837).
- [13] A.K. Lam, Lipomatous tumours in adrenal gland: WHO updates and clinical implications, *Endocr. Relat. Cancer* 24 (3) (2017 Mar) R65–R79, <https://doi.org/10.1530/ERC-16-0564> (Epub 2017 Jan 31. PMID: 28143811).
- [14] K.T. Montone, M. Rosen, E.S. Siegelman, F. Fogt, V.A. Livolsi, Adrenocortical neoplasms with myelolipomatous and lipomatous metaplasia: report of 3 cases, *Endocr. Pract.* 15 (2) (2009 Mar) 128–133, <https://doi.org/10.4158/EP.15.2.128> (PMID: 19289323).
- [15] K.Y. Lam, C.Y. Lo, Adrenal lipomatous tumours: a 30 year clinicopathological experience at a single institution, *J. Clin. Pathol.* 54 (9) (2001 Sep) 707–712, <https://doi.org/10.1136/jcp.54.9.707> (PMID: 11533079; PMCID: PMC1731508).
- [16] R.A. Agha, T. Franchi, C. Sohrab, G. Mathew, A. Kirwan, A. Thomas, et al., The SCARE 2020 guideline: updating consensus surgical case report (SCARE) guidelines, *Int. J. Surg.* 84 (1) (2020) 226–230.
- [17] Agrusa A, Romano G, Frazzetta G, Chianetta D, Sorce V, Di Buono G, et al. Laparoscopic Adrenalectomy for Large Adrenal Masses: Single Team Experience. *Int. J. Surg.* 12 (2014) S72–S74.
- [18] M. Han, A.L. Burnett, E.K. Fishman, F.F. Marshall, The natural history and treatment of adrenal myelolipoma. *J Urol.* 1997;157(4):1213-1216.nce, *Int. J. Surg.* 12 (2014) S72–S74.
- [19] I. Meteoglu, F. Kacar, N. Culhaci, F. Taskin, T. Öge, Adrenal myelolipoma: a case report, *Internet J. Urol.* (2004) 2.
- [20] C. Russell, B.W. Goodacre, E. Van Sonnenberg, E. Orihuela, Spontaneous rupture of adrenal myelolipoma: spiral CT appearance, *Abdom. Imaging* 25 (4) (2000) 431–434.