

Saw-scaled viper envenoming complicated with acute myocardial infarction

SAGE Open Medical Case Reports
Volume 9: 1–5
© The Author(s) 2021
Article reuse guidelines:
sagepub.com/journals-permissions
DOI: 10.1177/2050313X211007705
journals.sagepub.com/home/sco



Selladurai Pirasath¹ , Dilani Gajan¹, Mahesan Guruparan², Arumugam Muruganathan³ and Ariarane Gnanathan⁴

Abstract

The saw-scaled viper (*Echis carinatus*) is considered to be a venomous snake which is especially seen in Northern Sri Lanka. Systemic manifestations are rare and reported complications include coagulopathy and renal impairment. The cardiac toxicity following snakebites is rare and cardiac involvement following the saw-scaled viper bites is extremely rare. Here, we describe a patient with acute myocardial infarction following systemic envenoming by saw-scaled viper in Northern Sri Lanka, which was successfully managed per ward protocol following national guidelines.

Keywords

Saw-scaled viper, myocardial infarction, envenoming

Date received: 18 February 2021; accepted: 16 March 2021

Introduction

Snakebites are commonly encountered in clinical practice, especially in the dry zone of Sri Lanka, that is, the Northern part of the country. The saw-scaled viper (SSV) (*Echis carinatus*) is considered to be a venomous snake which is especially seen in Northern Sri Lanka.^{1,2} The clinical profile of the SSV is not well established due to its restricted distribution in Sri Lanka.^{1,3} The local envenoming and haematological manifestations are common among the SSV bites.^{1,2} Systemic manifestations are rare and reported complications include coagulopathy and renal impairment.^{4,5} The cardiac toxicity following snakebites is rarely reported, especially with the SSV bites in literature. The exact pathophysiology has not been established in literature. The biological plausibility for this association is due to the thrombotic and vasoconstricting properties of snake venom. Here, we describe a middle-aged man with acute myocardial infarction following systemic envenoming by SSV in Northern Sri Lanka.

Case history

A 50-year-old previously healthy farmer was admitted to emergency unit with a history of localised pain and swelling of left foot following the SSV bite after 1 h of the incident. The dead snake was brought by the patient and identified by medical professional and subsequently was confirmed by herpetologist as SSV (*E. carinatus*) (shown in Figure 1). The patient

had no past history or risk factors of ischaemic heart disease and had no significant past surgical history. On examination, the patient was conscious and alert. Patient had localised swelling and fang mark at the bite site without any localised bleeding manifestations. Patient's pulse rate was 80 beats/min and his blood pressure was 120/80 mmHg. Patient's respiratory rate was 12/min with oxygen saturation of 98% on room air. Patient had no signs of systemic envenoming. The 20-min whole blood clotting test (WBCT) showed incoagulable blood. Patient's full blood count showed white cell count of 8520/mm³, haemoglobin of 14 g/dL and platelets of 233,000/mm³. Liver enzymes were mildly elevated (aspartate transaminase (AST): 86 IU/L, alanine transaminase (ALT): 77 IU/L). Serum electrolytes revealed sodium of 140 mmol/L and potassium of 3.8 mmol/L. Blood urea was 44 mg/dL and serum creatinine was 1.06 mg/dL. Clotting profile, including PT/INR (prothrombin time/international normalized ratio) and APTT (activated partial thromboplastin time), was very high. His

¹District General Hospital, Kilinochchi, Sri Lanka

²Teaching Hospital, Jaffna, Sri Lanka

³Department of Parasitology, Faculty of Medicine, University of Jaffna, Jaffna, Sri Lanka

⁴National Hospital of Sri Lanka and Department of Medicine, Faculty of Medicine, University of Colombo, Colombo, Sri Lanka

Corresponding Author:

Selladurai Pirasath, District General Hospital, Kilinochchi, Ilavai North, Ilavai, Jaffna, Sri Lanka.

Email: selladurairasath81@gmail.com



initial electrocardiography (ECG) was normal (Table 1). Patient was initially managed with intravenous administration of 10 vials of Indian polyvalent anti-snake venom (ASV)



Figure 1. The dead specimen of saw-scaled viper (SSV) (*Echis carinatus*) which was brought by the patient.

along with intravenous hydrocortisone of 200 mg and intravenous chlorpheniramine of 10 mg. The 20-min WBCT was repeated 6 h later and it showed incoagulable blood again. Ten vials of ASV infusion were repeated along with intravenous hydrocortisone of 200 mg and intravenous chlorpheniramine of 10 mg.

Ten hours after SSV bite, patient developed ischaemic chest pain with autonomic symptoms. Patient was anxious and had profuse sweating. Twelve-lead ECG showed ST elevation in leads I, aVL and ST depression in II, aVF, V₄ to V₆ (shown in Figure 2). Patient's high sensitivity troponin I was positive (3051 ng/L). Patient was managed with loading doses of aspirin 300 mg, clopidogrel 300 mg, atorvastatin 40 mg and tenecteplase, followed by enoxaparin 1 mg/kg twice daily for 3 days. Patient's 2-dimensional echocardiography showed anterior, apical, apico-septal hypokinesia with ejection fraction of 50% suggestive of ischemic left ventricular dysfunction. One week later, coronary angiography was performed and showed normal coronary epicardial arteries (shown in Figure 3(a) and (b)). The anti-anginal drugs were discontinued, but antiplatelets and statins were continued.

Table 1. The biochemical profile of the patient is shown with clinical progression of disease.

Biochemical investigations	Admission	Day 1	Day 2	Day 3	Day 4	Day 5	Day 6
Full blood count							
White cell count (4000–11,000/mm ³)	6450	8520	10,800	10,100	7470	6820	6840
Neutrophils (50%–70%)	46	39	93	65	52	56	56
Lymphocytes (20%–40%)	43	52	4	30	33	29	36
Haemoglobin (12–16 g/dL)	13	14	13.6	13.1	12.8	12.9	13.1
MCV (80–100 fL)	87	92	93	91	93	94	92
Red cell count (400,000–550,000/mm ³)	448,000	440,000	410,000	398,000	398,000	397,000	410,000
Platelets (150,000–450,000/mm ³)	235,000	233,000	201,000	163,000	182,000	181,000	210,000
Renal functions tests							
Blood urea (18–55 mg/dL)	43	44	40	38	22	28	32
Serum creatinine (0.7–1.5 mg/dL)	1.03	1.06	0.99	1.1	1.06	1.1	1.1
Serum electrolytes							
Serum sodium (135–145 mmol/L)	136	140	138	138	138	134	135
Serum potassium (3.5–5.0 mmol/L)	3.9	3.8	3.7	4.1	3.6	3.8	3.9
Liver profile							
Serum AST (0–45 U/L)	46	86	78	44	42	40	40
Serum ALT (0–35 U/L)	57	77	70	38	38	32	38
Total bilirubin (0–2.0 mg/dL)	1.2	1.0	1.1	1.0	1.1	1.0	1.0
Indirect bilirubin (0–1.6 mg/dL)	0.8	0.8	0.8	0.7	0.9	0.8	0.8
Clotting profile							
PT/INR (<1.4)	Very high	Very high	Very high	1.2	1.0	1.1	1.2
APTT (<35)	Very high			32	34	32	35
Urine full report							
Protein (+)	–	Nil	–	Nil	–	–	Nil
Pus cells (/HPF)	–	1.2	–	3–4	–	–	3–5
Red cells (/HPF)	–	10–15	–	5–10	–	–	5–10
Active sediment (+)	–	Nil	–	Nil	–	–	Nil
High-sensitive Troponin I (<19 ng/L)		–	3051	1572	1025	572	109.2

MCV: mean corpuscular volume; AST: aspartate transaminase; ALT: alanine transaminase; PT/INR: prothrombin time/international normalized ratio; APTT: activated partial thromboplastin time.

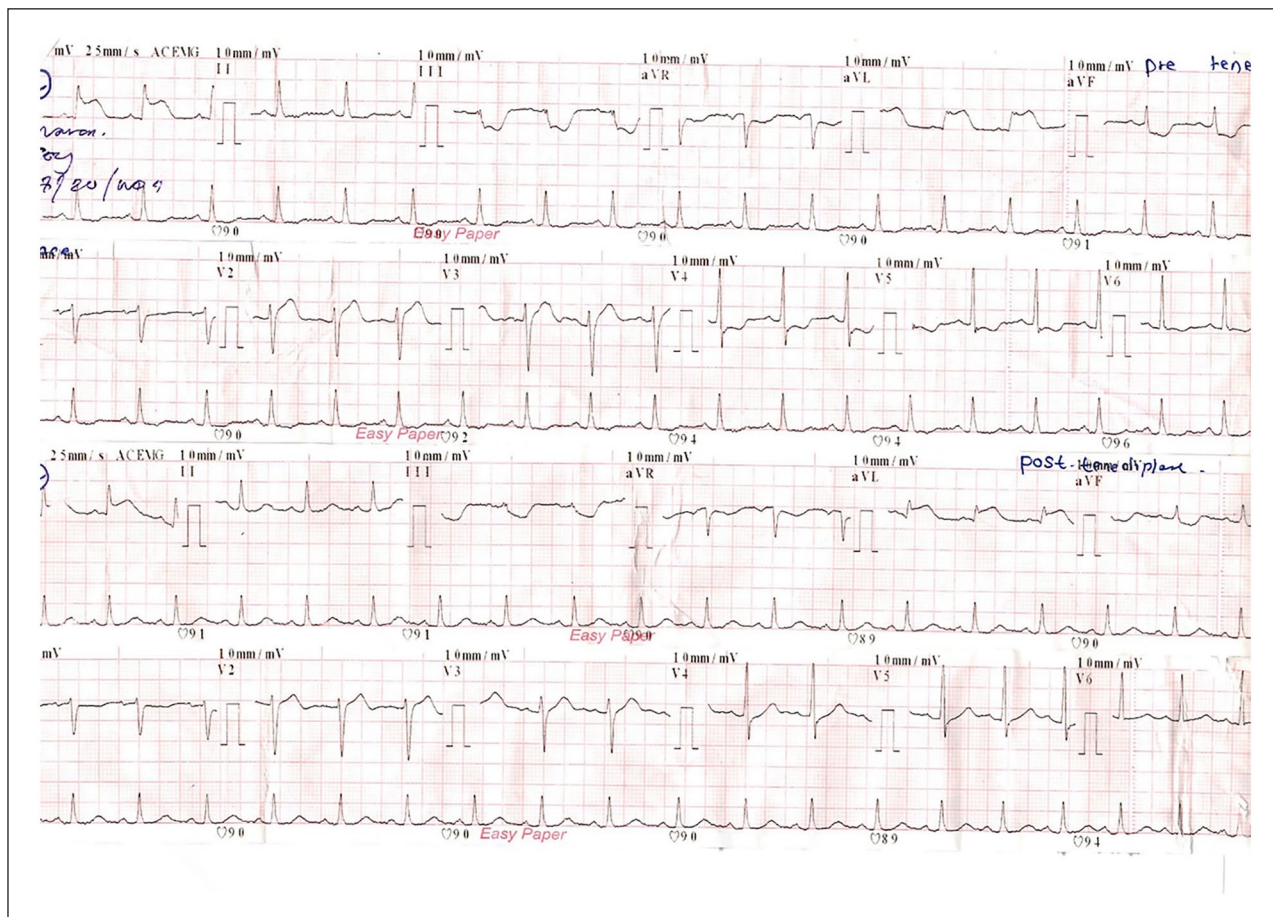


Figure 2. The 12-lead electrocardiography (ECG) showed ST elevation in leads I, aVL and ST depression in II, aVF, V₄ to V₆ pre-thrombolytic therapy and resolution of ECG changes following thrombolytic therapy in patient with saw-scaled viper (SSV) (*Echis carinatus*) envenomation.

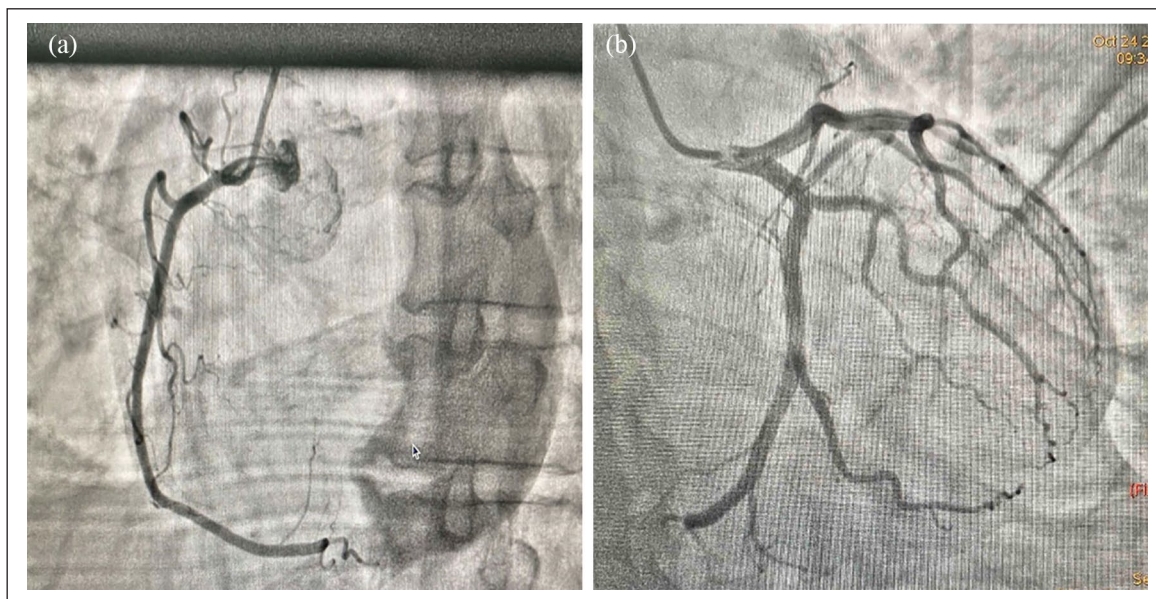


Figure 3. The coronary angiography showed normal (a) right and (b) left coronary arteries in the patient with saw-scaled viper (SSV) (*Echis carinatus*) envenomation.

Discussion

The SSV is considered to be one of the venomous snakes in Sri Lanka which is distributed in certain parts of Northern Sri Lanka and a few areas of Southern Sri Lanka.¹⁻³ The clinical profile of the SSV is not well established due to its restricted distribution in Sri Lanka.^{1,2} The first case of the SSV was described by Patrick Russell in 1796 in India in 1801.⁶ The SSV bites are rarely reported in Sri Lanka and SSV is limited to certain parts of dry zones of Sri Lanka, especially Northern Sri Lanka.^{1,2}

The local envenoming and haematological manifestations are common among the SSV bites which are reported in Sri Lanka.^{1,2} The pain, swelling and necrosis can occur due to phospholipase A2 component of the SSV venom. Spontaneous bleeding can occur due to the activation of prothrombin by metalloproteinase seen in the SSV venom.⁷ Consumptive coagulopathy occurs due to the activation of clotting system by procoagulant enzymes in the SSV venom which can cause hypofibrinogenemia and disseminated intravascular coagulation, resulting in multiorgan dysfunction and death.^{5,8} The SSV venom contains many other toxic compounds which activate to cause derangement in haemostasis such as platelet aggregation inhibitors, carinatin, echistatin, and echicetin, protein C activator, fibrinogenolysin, calcium-dependent carinactivase and disintegrins.⁹ However, the venom profiles differ from other geographically distinct venoms of *E. carinatus* due to change in the relative composition of the toxin families.¹⁰ Snake venom metalloproteinase, snakelecs and phospholipase A2 are major venom components in all the venoms.

The cardiac toxicity following snakebites is rarely reported, especially with the SSV bites in literature. Recently, some case reports of myocardial infarction have been reported following snakebites.¹¹ However, there have been a few published case reports of cardiac toxicity following Russell's viper¹² and a hump-nosed viper bite.^{13,14} The exact pathophysiology has not been established in literature. The biological plausibility for this association is due to the thrombotic and vasoconstricting properties of snake venom. Various pathophysiological mechanisms behind myocardial infarction following snakebite have been proposed which includes hypovolemic and anaphylactic shock,¹⁵ coronary thrombosis,¹⁶ direct cardiac toxic effect,¹⁷ coronary vasoconstriction, myocarditis with extensive myocardial necrosis and myocardial haemorrhage and microvascular thrombin deposition.¹⁸

Our patient developed local envenoming and haematological manifestations at the time of admission. Subsequently, patient developed acute myocardial infarction after 12 h of the SSV bite. ECG is recommended as the earliest diagnostic tool to detect myocardial infarction which may not show characteristic pattern in the hyper acute phase. Therefore, further diagnostic evaluation is necessary to diagnose myocardial infarction in snakebite patients.¹⁹ Our patient is confirmed by

electrocardiographic changes, positive troponin I and echocardiographic findings. Further coronary angiography findings were normal. Patient's fasting blood sugar and lipid profile were normal and he had no risk factors such as obesity, smoking, alcoholism, sedentary life style and family history of heart disease as well. Patient had no previous psychiatric disorders and did not have any anxiety following snake bite on psychiatric assessment. Furthermore, patient had not been given any premedications to predispose to myocardial infarction except anti-snake venom along with hydrocortisone and chlorpheniramine. Therefore, we conclude that acute myocardial infarction was purely due to SSV systemic envenomation. This was further evidenced by the absence of any cardiovascular risk factors or premedications or stress related to snake bite in our patient.

Immunotherapy is the only specific therapy for snakebite envenoming.^{1,2} The outcome depends on the ability of immunoglobulins to bind, extract and eliminate toxins present in the body. The treatment of myocardial infarction following snakebite is major clinical challenge because snake venom causes thrombocytopenia, coagulopathy and risk of bleeding.²⁰ These may limit the use of thrombolytic therapy. The thrombolytic therapy along with anti-anginal drugs are recommended for myocardial infarction following snakebite according to types of myocardial infarction in previous case reports in literature.^{11,12,19} However, our patient had already received two cycles of ASV and had normal basal tests, and was at low risk for bleeding. The prompt ASV therapy and monitoring for coagulation functions are essential for proper management of myocardial infarction following snakebite. The bacterial infections can occur at bite sites especially if bite site was incised or tampered by traditional treatments which may require local and systemic antibiotics.²¹ Our patient was managed with oral flucloxacillin for 5 days.

Conclusion

This case illustrates a patient with acute myocardial infarction which is a rare manifestation of the SSV envenoming following the SSV bite which was successfully managed per ward protocol following national guidelines.

Declaration of conflicting interests

The author(s) declared no potential conflicts of interest with respect to the research, authorship, and/or publication of this article.

Ethical approval

Our institution does not require ethical approval for reporting individual cases or case series.


Funding

The author(s) received no financial support for the research, authorship, and/or publication of this article.

Informed consent

Written informed consent was obtained from the patient for their anonymised information to be published in this article.

ORCID iD

Selladurai Pirasath  <https://orcid.org/0000-0002-4274-4919>

References

- Gnanathanan A, Rodrogo A, Peranantharajah T, et al. Case report: saw-scaled viper bites in Sri Lanka: is it a different subspecies? Clinical evidence from an authenticated case series. *Am J Trop Med Hyg* 2012; 86(2): 254–257.
- Kularatne SAM, Sivansuthan S, Medagedara SC, et al. Revisiting saw-scaled viper (*Echis carinatus*) bites in the Jaffna peninsula of Sri Lanka: distribution, epidemiology and clinical manifestations. *Trans R Soc Trop Med Hyg* 2011; 105(10): 591–597.
- Whitehall JS, Yarlani M, Arunthathy M, et al. Snakebites in north east Sri Lanka. *Rural Remote Health* 2007; 7: 751.
- Lakhotia M, Kothari D, Choudhri DR, et al. A case of saw-scale viper snakebite presenting as pleurapericardial hemorrhage. *J Indian Acad Clin Med* 2002; 3: 392–394.
- Ali G, Kak M, Kumar M, et al. Acute renal failure following *Echis carinatus* (saw-scaled viper) envenomation. *Indian J Nephrol* 2004; 14: 177–181.
- Cherlin VA. New facts on the taxonomy of the snakes of the genus *Echis*. *Smithsonian Herpetol* 1984; 61: 1–7.
- Cortelazzo A, Guerranti R, Bini L, et al. Effects of snake venom proteases on human fibrinogen chains. *Blood Transfus* 2010; 8(Suppl. 3): s120–S125.
- Visweswaran RK and George J. Snakebite induced acute renal failure. *Int J Nephrol* 1999; 9: 156–159.
- Mahadeswaraswamy YH, Nagaraju S, Girish KS, et al. Local tissue destruction and procoagulation properties of *Echis carinatus* venom: inhibition by *Vitis vinifera* seed methanol extract. *Phytother Res* 2008; 22(7): 963–969.
- Bhatia S and Vasudevan K. Comparative proteomics of geographically distinct saw-scaled viper (*Echis carinatus*) venoms from India. *Toxicon X* 2020; 7: 100048.
- Kariyanna PT, Jayarangaiah A, Kamran H, et al. Myocardial infarction after snakebite envenomation: a scoping study. *Scifed J Cardiol* 2018; 2(3): 21.
- Silva A, Pilapitiya S and Siribaddana S. Acute Myocardial Infarction following a possible direct intravenous bite of Russell's viper (*Daboia russelli*). *BMC Res Notes* 2012; 5: 500.
- Thillainathan S, Priyangika D, Marasinghe I, et al. Rare cardiac sequelae of a hump-nosed viper bite. *BMC Res Notes* 2015; 8(1): 4–7.
- Gunathilake IS, Bandara R, Abeysinghe T, et al. Cardiovascular involvement following a hump nosed viper bite – a rare complication. *J Postgrad Inst Med* 2020; 7(2): E1161–E1164.
- Brown R and Dewar HA. Heart damage following adder bite in England. *Br Heart J* 1965; 27: 144–147.
- Sarangi A, Jena I, Sahoo H, et al. A profile of snakebite poisoning with special reference to haematological, renal, neurological and electrocardiographic abnormalities. *J Assoc Physicians India* 1976; 25: 555–560.
- Chadha JS, Ashby DW and Brown JO. Abnormal electrocardiogram after adder bite. *Br Heart* 1968; 30: 138–140.
- Than-Than, Francis N, Tin-Nu-Swe, et al. Contribution of focal hemorrhage and microvascular fibrin deposition to fatal envenoming by Russell's viper (*Vipera russelli siamensis*) in Burma. *Acta Tropica* 1989; 46: 23–38.
- Gaballa M, Taher T, Brodin LA, et al. Myocardial infarction as a rare consequence of a snakebite diagnosis with novel echocardiographic tissue Doppler techniques. *Circulation* 2005; 112: e140–e142.
- Kariyanna PT, Jayarangaiah A, Kamran H, et al. Myocardial Infarction after Snakebite. *Scifed J Cardiol* 2018; 2(3): 21.
- Palappallil DS. Pattern of use of antibiotics following snake bite in a tertiary care hospital. *J Clin Diagn Res* 2015; 9(8): OC05–OC09.