

*Short Report***The iron and testosterone levels in amoebic liver abscess patients - a preliminary study from northern Sri Lanka**R Arujun,¹ T Kumanan,¹ V Sujanitha¹*Sri Lankan Journal of Infectious Diseases 2019 Vol.9 (2):141-145*DOI: <http://doi.org/10.4038/sljid.v9i2.8245>**Abstract**

Amoebic liver abscesses (ALA) are observed among adult males who consume locally brewed alcohol in the tropics. The contributory role of alcohol-induced hepatic iron stores and the male hormone testosterone were said to be playing a pivotal role in the pathogenesis of ALA. This descriptive preliminary study was intended to see a possible relationship of serum iron profile and testosterone level among toddy (a local palm wine) drinkers who presented with ALA to the Teaching Hospital Jaffna. Results have shown very high serum ferritin levels (902.58ng/ml) in these patients with ALA. However, the serum iron levels (43.05µg/dl) and the transferrin saturation levels (22.01%) were observed to be normal or below normal and Total Iron Binding Capacity (TIBC) level was unexpectedly low (193.3µg/dl) for the corresponding low serum iron levels. Furthermore, the serum testosterone level (2.44ng/ml) was also low or low normal when compared with the reference range in the study population. As this preliminary study contrasts with previously postulated theories, further study is recommended to arrive at a concrete conclusion.

Introduction

Amoebic liver abscess (ALA) has been a common public health problem over many centuries. The magnitude of the problem is enormous, particularly in the tropics. Studies from the Indian subcontinent in the recent past clearly demonstrate its persistent nature and its detrimental impact on the health-care cost of low middle-income countries of this region. A recent study from India found that active bleeding from the colon is unexpectedly high in these ALA patients leading to very high morbidity and mortality.^{1,2}

Epidemiological studies have shown that ALA is common in adult males who are habitual drinkers of the indigenously brewed alcohol beverage toddy, which is a palm wine obtained from the palmyra tree (*Borassus flabellifer*).³ Owing to the scarcity of evidence to say that the contamination of these beverages with amoebae is minimal, several mechanisms have been put forward from time to time to explain the pathogenesis of ALA in this vulnerable group.⁴

¹University Medical Unit, Teaching Hospital Jaffna, Sri Lanka

Address for correspondence: Dr R Arujun, Teaching Hospital, Jaffna, Sri Lanka Telephone: +94 771546924

Email: arujun1987@gmail.com  <https://orcid.org/0000-0001-8502-9934>

Received 9 May 2019 and revised version accepted 14 August 2019



This is an open-access article distributed under the terms of the Creative Commons Attribution License, which permits unrestricted use, distribution, and reproduction in any medium, provided the original author and source are credited.

Amoebiasis and ALA pose serious public health issues in the Northern Province of Sri Lanka.⁵ *Entamoeba histolytica* was recently confirmed as a common cause of these clinically diagnosed liver abscesses in northern Sri Lanka.⁶

Several factors have been postulated to play a role in the development of ALA in adult males who consume locally brewed beverages. The contributory role of alcohol-induced hepatic iron stores and the male hormone testosterone have been suggested as playing an important role in the pathogenesis of ALA.⁷ Although human studies are lacking, testosterone level determines susceptibility to ALA in mouse models.⁸ The present study describes the testosterone level and serum iron profile of these ALA patients.

Methods

This study was conducted at the Teaching Hospital, Jaffna, which is the only tertiary care center in the Northern Province of Sri Lanka. Twenty patients who were treated in the medical wards for ALA within a period of 3 months in 2018 were randomly recruited. Amoebic liver abscess was confirmed in these patients ultrasonically. Blood samples were obtained from all the patients on discharge after clinical resolution of symptoms with metronidazole alone. Informed written consent was obtained from the study participants and ethical approval for the study was obtained from the Directorate of the Teaching Hospital, Jaffna. A control group was not included for this non-interventional study.

Basic demographic details were taken from the patients who were confirmed with liver abscess. From each patient 2ml of blood was taken for the analysis of testosterone levels and a full iron profile, including serum ferritin, total iron, transferrin saturation, total iron binding capacity, unfractionated iron binding capacity. Enhanced chemiluminescence immune assay was used to measure these parameters.

Results

All 20 patients were male toddy drinkers treated only with metronidazole. The distribution of the iron profile with different age groups is given in Table 1, while Figure 1 shows the testosterone level in the different age groups. Figure 2 shows the level of transferrin saturation in these age groups.

Table 1: Iron studies in patients with ALA

Age groups (in years)	Number of patients	Ferritin mean value (ng/ml)	Iron mean value (µg/dl)	TIBC Mean value (µg/dl)	Haemoglobin levels (g/dl)
25 – 39	7	850.54	36.7	169.3	12.74
40 – 54	5	975.46	64	224	12.04
55 – 69	5	1106.38	32.2	143.6	10.94
70 – 84	3	562.86	41	163.3	10.23

The results showed very high serum ferritin levels. Among the participants, 16 out of 20 patients have serum ferritin more the 500ng/ml with a mean value of 902.58ng/ml. Mean value of serum iron levels and the transferrin saturation levels were 43.05µg/dl (33 -193) and 22.01% (15 -35) respectively which was within the range of normal population. Mean value

of TIBC was 193.3 μ g/dl (228 -428) which is also unexpectedly low for the corresponding serum iron levels. The mean value of serum testosterone level was 2.44ng/ml (2.7 – 10.7) which is low for the reference range in this study population.

Fig.1: Serum testosterone levels with different age groups in patients with ALA

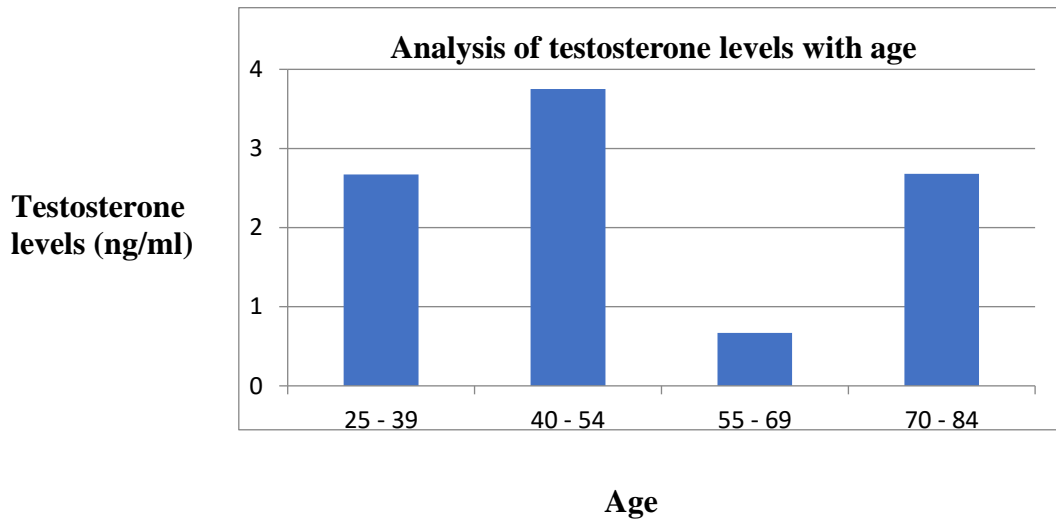
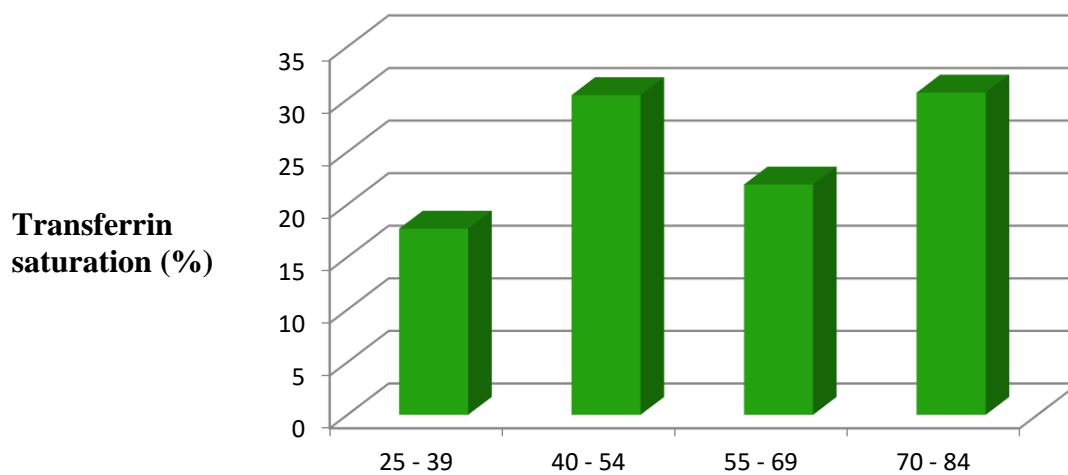


Fig. 2: Percentage transferrin saturation with age in patients with ALA



Discussion

Iron and testosterone have been implicated in previous studies by several investigators in the pathogenesis of hepatic amoebiasis.⁷ This simple observational preliminary study was designed to describe these two factors in patients with ALA.

The results have shown very high serum ferritin levels in 80 percent of patients with ALA. The mean value of serum ferritin was 902.58ng/ml. Studies done in the past too have shown that the serum ferritin was high among patients with ALA.⁹ The postulated explanations are that ferritin being an acute phase reactant is expected to be elevated in infection with *Entamoeba histolytica* and different pathogenic processes are discussed as possible reasons for elevated serum ferritin level in inflammation.⁹ It is reasonable to assume that though the blood samples were taken on discharge, it may take time for the acute phase protein levels to normalize. A follow up measurement of ferritin in these patients would be more informative of their actual iron status.

Serum iron levels (43.05µg/dl) and the transferrin saturation levels (22.01%) of the study population were observed to be within the reference range. The TIBC level was 193.3µg/dl which is also unexpectedly low for the corresponding serum iron levels which range from 36.7µg/dl to 64µg/dl. The presence of anaemia in these patients can partly explain these findings.

Anaemia is common in ALA, both due to the chronic infection leading to anemia of chronic disease and due to the commonly prevailing iron deficiency in developing countries. Anaemia promptly responding to amoebicidal drugs favors anaemia of chronic disease rather than iron deficiency.¹⁰ A detailed study including blood picture, bone marrow iron store levels will accurately determine the iron status of these patients.

Serum testosterone levels (2.44ng/ml) are low for the reference range in this study population. This finding contradicts with a laboratory-based study that found testosterone increased the susceptibility of mice to *Entamoeba histolytica* liver abscess by reducing the interferon-gamma secretion by natural killer cells but human studies are lacking.¹¹ A further, well designed prospective cohort study would be favorable to explore this observation. It has been suggested, based on animal models (hamster), that the male hormone testosterone could be a host factor that favors the development of ALA.⁴ The positive role of testosterone could be one of the explanations that middle-aged men were mostly affected, with ALA reaching a peak by the age of 40 years. With increasing age (after 50 years) the incidence declines with the reduction of testosterone levels. In fact, a rise in serum testosterone level noted in the elderly age group cannot be extrapolated as the number of patients in the elderly age group is comparatively low.

Conclusion

This study shows a complex iron profile and difference in the testosterone levels compared to the postulated theories in the past. A small number of samples and coexisting anemia may have influenced the results which are not in par with the previously postulated explanations. A further well designed prospective cohort study with a larger number of samples and more precise statistical analysis of the clinical profile, evaluation of anaemia and other confounding causes that could influence the iron studies would be recommended to study the correlation of these two widely attributed risk factors for developing invasive ALA.

Conflicts of Interest

The authors declare that they have no conflicts of interest.

References

1. Shobna JB, Sridhar S. Amoebic liver abscess with synchronous colitis: Lessons learnt in recent times. *Journal of Associations of Physicians of India* 2019; 67:11-12 No doi
2. Shivani D, Madhumita P, Devaraja D et al. Clinical and endoscopic management of synchronous amoebic liver abscess and bleeding colonic ulcers. *Journal of Associations of Physicians of India* 2019; 67:14-18 No doi
3. Kumar R, Priyadarshi RN, Anand U. Toddy consumption and amoebic liver abscess in India: An unexplored link. *Indian J Public Health* 2019; 63:89-90
doi: http://doi.org/10.4103/ijph.IJPH_192_18
4. Chadee K, Meerovitch E. The pathogenesis of experimentally induced amoebic liver abscess in the gerbil (*Meriones unguiculatus*). *Am J Pathol* 1984; 117(1):71–80 PMID: 6385727 PMCID: PMC1900557
5. Kannathasan S, De Silva NR, Kumanan T. Persistence of amoebiasis in northern Sri Lanka – a public health failure. *Journal of the Ceylon College of Physicians* 2017; 48:88-89
doi: <http://doi.org/10.4038/jccp.v48i2.7829>
6. Kannathasan S, Murugananthan A, Kumanan T et al. Amoebic liver abscess in northern Sri Lanka: first report of immunological and molecular confirmation of aetiology. *Parasit Vectors* 2017; 10:14 doi: <http://doi.org/10.1186/s13071-016-1950-2>
7. Makkar RP, Sachdev GK, Malhotra V. Alcohol consumption, hepatic iron load and the risk of amoebic liver abscess: a case-control study. *Intern Med* 2003; 42(8):644-9
doi: <http://doi.org/10.2169/internalmedicine.42.644>
8. Lotter H, Helk E, Bernin H et al. Testosterone increases susceptibility to amoebic liver abscess in mice and mediates inhibition of IFN γ secretion in natural killer T cells. *PLoS One* 2013; 8:2
doi: <http://doi.org/10.1371/journal.pone.0055694>
9. Bolarin DM. Serum ferritin in Nigerian patients with amoebic liver abscess and other tropical infections with liver involvement. *Acta Trop* 1983; 40(2):159-64 PMID: 6136177
10. Mayet FGH, Powell SJ. Anemia associated with amoebic liver abscess. *The American Journal of Tropical Medicine and Hygiene* 1964; 13(6):790–793
doi: <https://doi.org/10.4269/ajtmh.1964.13.790>
11. Kumanan T, Sujaritha V, Balakumar S et al. Amoebic liver abscess and indigenous alcoholic beverages in the tropics. *Journal of Tropical Medicine* 2018; Article ID 6901751
doi: <http://doi.org/org/10.1155/2018/6901751>