

## Mucinous adenocarcinoma of renal pelvis in a crossed ectopic kidney

S. Rajendra, M. Sivashankar

University Surgical Unit, Teaching Hospital, Jaffna, Sri Lanka

**Keywords:** Mucinous adenocarcinoma; renal pelvis; renal tumour; urolithiasis

### Introduction

Most renal tumours arise from renal parenchyma. Urothelial carcinomas constitutes less than 10 % of renal tumours. Less than 1% of renal pelvic epithelial malignancies are adenocarcinoma [1]. Mucinous adenocarcinoma (MA) of renal pelvis is extremely rare and constitutes less than 0.3% of renal pelvic tumours [2]. We report a case of mucinous adenocarcinoma of crossed ectopic renal pelvis occurring in association with pyonephrosis secondary to obstruction by a large staghorn calculus.

### Case report

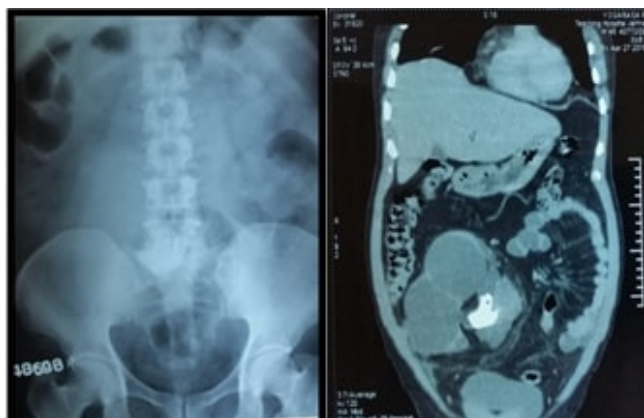
A 46-year-old Sri Lankan Tamil male patient presented with right lower abdominal pain and fever for one week. He had haematuria on and off for the past 5 years for which he did not get treatment. He was passing milky urine for the last three months. He had a tender intra-abdominal mass palpable in the right iliac fossa.

His urine full report and blood analysis confirmed a severe urinary tract infection. The x ray KUB demonstrated a large

staghorn calculus in the midline at the level of L5 vertebra (figure 1). Renal ultrasound (USS-KUB) and CT KUB revealed left kidney being situated below the right kidney. There was a cystic mass in left kidney with dilated pelvicalyceal system with no measurable renal cortex and a large staghorn calculus within renal pelvis. Right kidney and ureter were normal. The radiological diagnosis was crossed ectopia of nonfunctioning left kidney with large staghorn calculus and hydronephrosis (figure 1). He responded well to intravenous antibiotic treatment.

A lower midline laparotomy & nephrectomy for non-functioning crossed ectopic left kidney was performed after a month. The crossed ectopic left kidney was found as a large cystic mass located in the right iliac fossa extending up to just left of the midline at the level of L5 vertebra. It was supplied by two separate vascular pedicles which were originating from the left common iliac artery. The right kidney and ureter were identified and preserved. Severe adhesions and inflammatory response were noted between the left kidney and perirenal tissue.

The enlarged kidney measured 11 x 10 x 08 cm with a large staghorn calculus measuring 5 x 4 x 3 cm. The staghorn calculus was tightly impacted in the renal pelvis. A whitish



**Figure 1.** X ray KUB and CT KUB revealing large staghorn Calculus at the level of L5 vertebra level and crossed ectopia of left kidney with hydronephrosis and calculus respectively

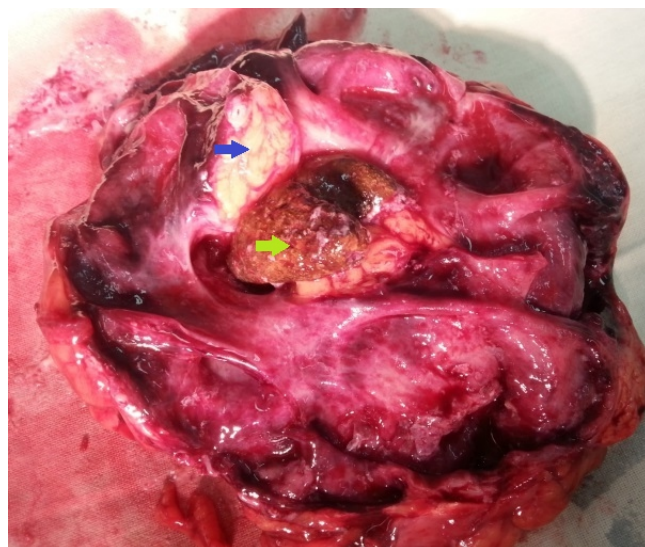Correspondence: S. Rajendra

E-mail: dr.s.rajendra@gmail.com

Received: 08-04-2018 Accepted: 12-07-2018

 <http://orcid.org/0000-0002-3303-603X>

DOI: <http://doi.org/10.4038/sljs.v36i3.8527>



**Figure 2.** This image shows the tumour at pelvic ureteric junction (blue arrow) and staghorn calculus impacted within dilated pelvis (by green arrow).

lobulated area was noted in the renal pelvis (figure 2).

Histopathology report of this specimen revealed excessive dilatation of pelvicalyceal system with mucinous metaplasia and dysplasia. Thinned out renal parenchyma had sclerosed glomeruli and tubules in fibrotic stroma. A whitish lobulated area near the pelviureteric junction, measuring 40x 30 x 30 mm, was a poorly differentiated adenocarcinoma composed of lobules and irregular cell islands in a haemorrhagic necrotic background. The tumour infiltrated into perinephric fat.

He had an uneventful post-operative recovery. Following oncology referral, he was given limited radiotherapy to left ectopic renal bed after insertion of indwelling ureteric (JJ) stent to the right ureter.

### Discussion

Hasebe et al first described renal pelvic mucinous adenocarcinoma in 1960 (3). Since then few cases with mucinous adenocarcinoma have been reported mainly from Asian countries. MA occurring in ectopic kidney and horseshoe kidney are extremely rare [1].

The pathogenesis of MA is multi factorial. Glandular metaplasia of urothelium can occur due to chronic irritation, existing teratoma and epithelial sequestration during renal parenchymal development [2]. In our patient, the presence of staghorn calculus and pyonephrosis signifies the possibility of chronic irritation and ectopic nature of kidney points to the likelihood of epithelial sequestration. Apart from renal pelvis, the MA can be located in renal calyces, ureter and in urinary bladder [4].

Most of the patients with MA have no symptoms. Few can present with passing blood or mucous in urine, loin pain and ballotable intra-abdominal masses [4]. Our patient presented with haematuria, pyuria, fever and abdominal pain mimicking urinary tract infection. He also had an intra-abdominal mass in right lower abdomen suggesting an ectopic nature of kidney.

Imaging plays a key role in the diagnosis and staging of renal tumours. Thus the management is usually decided upon the findings of CT – IVU. This may not be applicable in the case of mucinous adenocarcinoma of renal pelvis [5]. Furthermore the mucinous cystadenomas can have varying morphologies that are radiologically categorized in different Bosniak classifications [4]. Decision making on the need for surgical intervention is quite difficult in this situation. In our patient the CT – KUB revealed an obstructed crossed ectopic left kidney with hydronephrosis and thinned out renal cortex suggesting a non functioning renal system. Thus an IVU was not performed in this patient.

Our patient had clinical and radiological diagnosis of crossed ectopic left kidney with hydronephrosis due to obstruction of renal pelvis by a staghorn calculus. Since it was a non-functioning kidney with pyonephrosis, it was decided to proceed with nephrectomy. MA of renal pelvis was only identified by histopathological examination of the nephrectomy specimen.

The exact diagnosis of this type of tumour is made after the pathologic examination of specimen. Characteristic pathologic features of MA are the stratified columnar epithelium with vacuolated cytoplasm and hyperchromatic pleomorphic nuclei. Signet ring cells in mucin substance are also seen. Infiltration into renal parenchyma, breach in the capsule and extension into the perinephric fat are features of local infiltration [2]. Clinical suspicion of MA is of utmost importance when dealing with cysts filled with large pools of mucin and gelatinous solid areas [1]. This type of tumour has been reported in congenitally abnormal kidneys [6]. Our patient had locally advanced MA based on histopathological report.

The treatment of MA is nephro ureterectomy with removal of cuff of urinary bladder [1]. The ideal treatment may not be possible in most instances as MA is seldom diagnosed pre operatively. Careful dissection of cysts is of utmost importance to prevent tumour seedling. In this patient the left lower ureter was not excised and he would need a second exploration for the lower ureter. This case was discussed at the multidisciplinary team (MDT) meeting and it was decided to delay the second surgery as he had locally advanced tumour with infiltration of renal bed. It was also decided to give limited radiotherapy to renal bed of ectopic left kidney. Very good response to chemotherapy with oxaliplatin, fluorouracil, leucovorin (FOLFOX4) has been reported in similar tumours occurring in urinary bladder [7]. Because of the high local recurrence of this tumour, it is mandatory that the patient will have to be followed up regularly at frequent intervals. Regular screening with USS-KUB and flexible cystoscopy has been planned for this patient.

### Conclusion

MA of renal pelvis is rare. MA occurring in crossed ectopic kidney is extremely rare. In our patient staghorn calculus, hydronephrosis, infection, inflammation and chronic irritation could have predisposed to glandular metaplasia in renal pelvis leading to MA.

All authors disclose no conflict of interest. The study was conducted in accordance with the ethical standards of the relevant institutional or national ethics committee and the Helsinki Declaration of 1975, as revised in 2000.

## References

1. Raphael V, Sailo S, Bhuyan A, Phukan M. Mucinous adenocarcinoma of the renal pelvis with adenocarcinoma in situ of the ureter. *Urology annals*. 2011 Sep;3(3):164. doi: 10.4103/0974-7796.84951
2. Yadav R, Kataria K, Balasundaram P, Karak AK. Mucinous cystadenocarcinoma arising in an ectopic kidney simulating a retroperitoneal dermoid cyst: a rare tumour presenting as a diagnostic dilemma. *The Malaysian journal of pathology*. 2013 Jun 1;35(1):95. <https://search.proquest.com/openview/8e9ba3f1e8a45fca6365754c48a32f2e/1?pqorigsite=gscholar&cbl=996340>
3. Fareghi M, Mohammadi A, Madaen K. Primary mucinous cystadenocarcinoma of renal pelvis: a case report. *Cases journal*. 2009 Dec;2(1):9395. doi: 10.1186/1757-1626-2-9395
4. Tepeler A, Erdem MR, Kurt O, Topaktas R, Kilicaslan I, Armağan A, Onol SY. A Rare Renal Epithelial Tumor: Mucinous Cystadenocarcinoma Case Report and Review of the Literature. *Case Reports in Medicine*, vol. 2011, Article ID 686283, 4 pages, 2011. <https://doi.org/10.1155/2011/686283>. doi:10.1155/2011/686283
5. Kaur G, Naik VR, Rahman MN. Mucinous adenocarcinoma of the renal pelvis associated with lithiasis and chronic gout. *Singapore medical journal*. 2004 Mar;45(3):125-6. <http://citeseerx.ist.psu.edu/viewdoc/download?doi=10.1.1.494.4563&rep=rep1&type=pdf>
6. Ross, D.G. and D'Amato, N.A., 1986. Papillary Mucinous Cystadenoma of Probable Renal Pelvic Origin in a Horseshoe Kidney. *The Journal of Urology*, 135(3), p.655
7. Tatli, A.M., Uysal, M., Goksu, S.S., Arslan, D., Gunduz, S., Ozdogan, M., Coskun, H.S., Bozcuk, H. and Savas, B., 2012. Primary mucinous adenocarcinoma of the bladder: complete response with FOLFOX-4 regimen. *Medical Oncology*, 29(3), pp.1935-1937. doi: <https://doi.org/10.1007/s00464-010-1054-6>

### Learning Points:

- MA is rare tumour of kidney and pre-operative diagnosis is difficult.
- Possibility of MA should be kept in mind in patients with enlarged cystic ectopic non-functioning kidney.