



Case report

A young patient with prostatic carcinoma with testicular metastasis

B. Balagobi^{a,*}, S. Gobishangar^a, S.T. Sarma^a, R.T. Brammah^b, A. Jenil^c^a University Surgical Unit, Teaching Hospital Jaffna, Sri Lanka^b University Medical Unit, Teaching Hospital Jaffna, Sri Lanka^c Department of Radiology, Teaching Hospital Jaffna, Sri Lanka

ARTICLE INFO

Keywords:

Prostate cancer
Secondary
Testicular
Metastasis
Case report
Young

ABSTRACT

Prostate cancer is one of the most frequent cancers in males and commonly a disease of the older population, but it is increasingly seen among older adolescents and young adults. The common sites of metastasis of prostatic carcinoma are bones and regional lymph nodes. Testicular metastasis from prostatic carcinoma is an infrequent presentation. We report a case of a young patient with prostatic carcinoma and multiple metastases, including bilateral testis. A 40-year-old male presented with lower urinary tract voiding symptoms and back pain for three months. His prostate-specific antigen level was elevated at 13.98 ng/ml. A magnetic resonance imaging of the prostate revealed two PIRADS V lesions and metastases in multiple bones and regional lymph nodes. On follow up, the patient complained of bilateral testicular swelling and ultrasound scan of the testes revealed bilateral testicular metastasis. Fine needle aspiration cytology of right-side testicular lesion revealed malignant cells compatible with metastasis from prostate cancer. Later involvement of multilevel vertebral and skull metastases was identified by magnetic resonance imaging. A T_{3b}N₁M_{1c} staging of prostate cancer was made, androgen deprivation therapy followed by chemo and radiotherapy was instituted, following extensive discussion with the patient. Unfortunately the patient succumbed to the illness during the course of treatment. This case report is of a patient with rare presentation of bilateral testicular metastasis with prostate cancer in young age.

1. Introduction

A recent analysis identified around 9 % of prostatic cancer cases are in men aged 35 to 54 years [1]. Metastasis from primary prostate cancer at the time of diagnosis is more common in men aged less than 50 years compared with advanced age [2]. Although testicular metastasis from prostatic carcinoma is seldom reported, testicular metastasis is incidentally found in up to 4 % of the patients who underwent bilateral orchidectomy to treat advanced prostate cancer [3]. The common sites of prostate cancer metastases are regional lymph nodes and bones followed by lung, liver, and adrenal glands [4]. We report a case of a young patient with prostatic carcinoma with multiple metastases of regional lymph nodes, bones and bilateral testicular metastasis and was drafted in line with the SCARE 2020 criteria [5].

2. Case presentation

A 40-year-old male patient presented with a history of severe voiding lower urinary tract symptoms of hesitancy, poor stream and

intermittent flow of urine and back pain for three months. A digital rectal examination was suggestive of T4 prostate cancer and Prostate-specific antigen (PSA) level was elevated at 13.98 ng/ml. Ultrasound scan of kidneys, ureters, bladder, and prostate (USKUBP) showed heterogeneous hypo-echoic prostate and uroflowmetry read a maximum flow rate (Qmax) of 11.5 ml. Diagnostic flexible cystoscopy revealed a malignant growth from the prostate and a prostatic urethra with stenosis and fibrosis. The patient underwent urgent magnetic resonance imaging (MRI) of prostate, pelvis, and abdomen. It revealed two PI-RADS V lesions (Fig. 1); one in the anterior aspect of the peripheral zone (with three nodular bladder base infiltration) and another nodule in the right posterolateral aspect of the peripheral zone. In addition, MRI revealed an isolated bladder mucosal deposit in the right anterolateral bladder wall, right neurovascular bundle infiltration with a nodular deposit, multiple pelvic lymph nodes (perivesical, left side external iliac) and multiple bone metastasis (both pubis, ischial tuberosity, right side femur) compatible with a tumor staging of T_{3b}N₁M_{1c}. On follow up, the patient complained of bilateral testicular swelling and discomfort (Fig. 2) and an ultrasound scan of the testis demonstrated bilateral

* Corresponding author.

E-mail address: b.balagobi@yahoo.com (B. Balagobi).<https://doi.org/10.1016/j.ijscr.2022.107653>

Received 11 August 2022; Received in revised form 7 September 2022; Accepted 10 September 2022

Available online 13 September 2022

2210-2612/© 2022 Published by Elsevier Ltd on behalf of IJS Publishing Group Ltd. This is an open access article under the CC BY-NC-ND license (<http://creativecommons.org/licenses/by-nc-nd/4.0/>).

multifocal malignant deposits (Fig. 1B) (His LDH level was 546 IU/l, AFP was 3.7 ng/ml, and beta HCG was 1.36 mIU/ml). Fine needle aspiration cytology of right-side testicular lesion confirmed a neoplastic epithelial cell proliferation (Fig. 3). In a multidisciplinary team discussion with urologist, radiologist, oncologist and a pathologist, above lesions were concluded to be compatible with metastatic prostate carcinoma including the secondaries in testes. On further evaluation, multiple metastatic deposits were noted in the skull and thoracolumbar vertebrae as well. The patient was initiated on treatment with GnRH analogue, combined with chemo and radiotherapy. Subsequently patient succumbed to the illness during the course of the treatment.

3. Discussion

Prostatic carcinoma is a disease of the elderly, but it is not uncommon in men younger than 55 years [1]. Testicular metastasis from prostatic carcinoma is very uncommon [4]. However, the commonest primary site for testicular metastasis is the prostate (15 %) also testicular metastases might be considered an unusual additional factor of poor prognosis [6]. Prostate cancer commonly metastasizes to bones and lungs, but metastasis to the bilateral testis are rare and associated with a poor prognosis [7]. In a cohort study of 1589 patients with prostatic cancer hematogenous metastases were present in 35 % of patients [8]. The most frequent involvements were, bone (90 %), lung (46 %), liver (25 %), pleura (21 %), adrenals (13 %), and metastasis in the testes were found only in a few. Androgen deprivation therapy (ADT) with gonadotropin-releasing hormone (GnRH) agonists and antagonists is the mainstay of treatment in advanced prostate cancer [9,10]. In addition, combined hormonal therapy with chemo and radiotherapy improves outcomes in advanced prostate cancer [11]. The survival after diagnosing testicular metastasis of primary prostatic carcinoma is usually less than one year [12,13]. As in this case, the testicular metastasis can behave aggressively and further reduce the patient's survival.

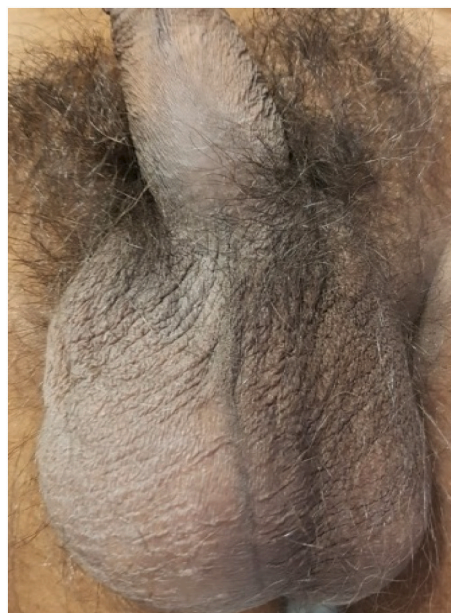

Fig. 2. Bilateral testicular swelling.

4. Conclusion

Prostate cancer is common among older men. However, it is usually more aggressive in young males than elderly. Though testicular metastasis of prostatic carcinoma in a young male is one of the unusual presentations, it purports a poor prognosis and a reduced patient survival. Testicular metastasis often behaves aggressively, so early suspicion of testicular metastasis is essential when there is a scrotal swelling in a patient with prostatic cancer. Early diagnosis and combined treatment

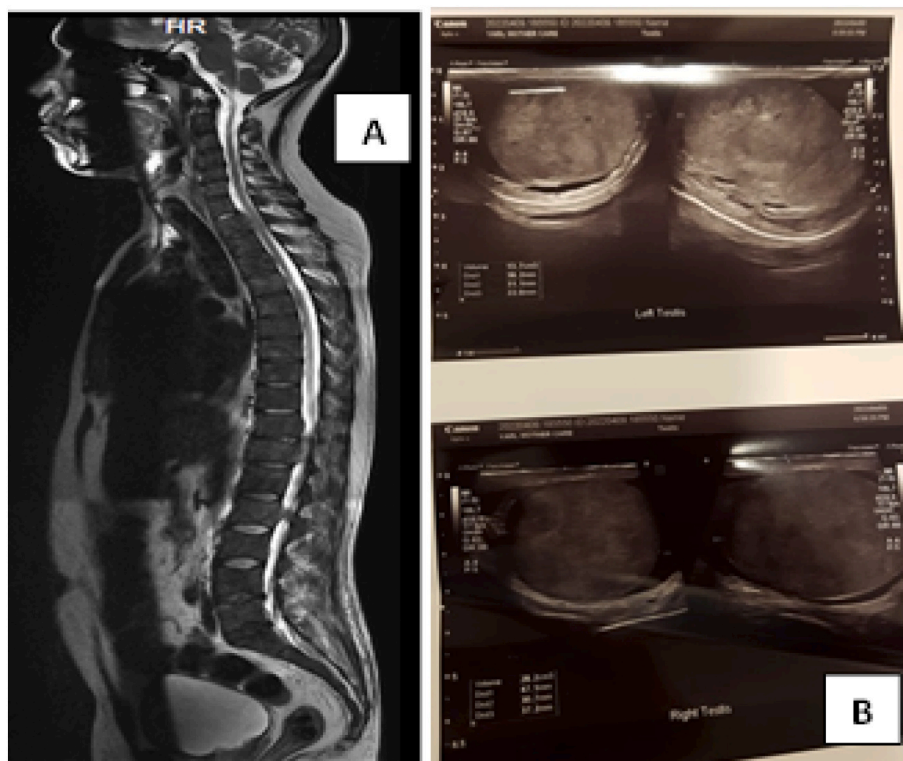


Fig. 1. (A): Magnetic resonance image shows prostatic lesion and multilevel thoracolumbar vertebral and skull metastasis (B): Ultrasound scan shows bilateral testicular lesions.

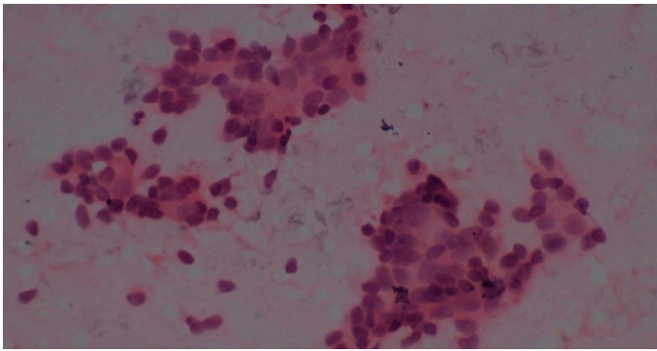


Fig. 3. Fine needle aspiration cytology of testis shows neoplastic epithelial cell proliferation.

with GnRH analogue or antagonist, radiotherapy and chemotherapy can improve the outcome in advanced prostatic carcinoma.

Sources of funding

None.

Ethical approval

N/A.

Statement of informed consent

Written informed consent was obtained from the patient for publication of this case report and accompanying images. A copy of the written consent is available for review by the Editor-in Chief of this journal on request.

Research registration

N/A.

Guarantor

Dr. B. Balagobi, Corresponding author

CRediT authorship contribution statement

Study concept- Balagobi. B

Data collection - Gobishangar S and Jenil A

Data analysis – Sarma S.T and Brammah R.T

Declaration of competing interest

There is no conflict of interest between the authors as everybody is aware of the work and participated actively and equally.

Acknowledgment

The authors wish to thank, S. Thiruvarangan, Research Assistant who assisted to this manuscript preparation and submission process in the final stage of this article.

References

- [1] H.E. Rahardjo, R. Umbas, H. Sutisna, Testicular metastases from prostate carcinoma, *Asian J. Surg.* 33 (3) (2010) 154–156, [https://doi.org/10.1016/S1015-9584\(10\)60026-7](https://doi.org/10.1016/S1015-9584(10)60026-7). PMID: 21163414.
- [2] K.M. Waisanen, T. Osumah, S.S. Vaish, Testicular metastasis from prostatic adenocarcinoma presenting as recurrent epididymo-orchitis, *Urology* 108 (2017) e7–e9, <https://doi.org/10.1016/j.urology.2017.07.029>. Epub 2017 Jul 28 PMID: 28760557.
- [3] S. Smelzo, G. Mantica, R. Lucianò, N.P. Tenace, D. De Marchi, G. Pini, G. Passaretti, A. Losa, F. Gaboardi, Prostate cancer testicular metastasis: Are they underestimated? Case report and analysis of the literature, 3915603211009118, *Urologia* (2021), <https://doi.org/10.1177/03915603211009118>. Epub ahead of print. PMID: 33832367.
- [4] A.J. Tiltman, Metastatic tumours in the testis, *Histopathology* 3 (1) (1979) 31–37, <https://doi.org/10.1111/j.1365-2559.1979.tb02979.x>. PMID: 428920.
- [5] R.A. Agha, T. Franchi, C. Sohrabi, G. Mathew, The SCARE 2020 guideline: updating consensus Surgical Case Report (SCARE) guidelines, *Int. J. Surg.* 84 (2020) 226–230.
- [6] F. Korkeas, R. Gasperini, K.L. Korkeas, D.C. Silva Neto, M.G. Castro, Testicular metastases: a poor prognostic factor in patients with advanced prostate cancer, *World J. Urol.* 27 (1) (2009) 113–115, <https://doi.org/10.1007/s00345-008-0322-8>. Epub 2008 Sep 2 PMID: 18762947.
- [7] A. Kusaka, T. Koie, H. Yamamoto, I. Hamano, T. Yoneyama, Y. Hashimoto, C. Ohyama, Y. Tobisawa, T. Yoneyama, Testicular metastasis of prostate cancer: a case report, *Case Rep. Oncol.* 7 (3) (2014) 643–647, <https://doi.org/10.1159/000367779>. PMID: 25408658; PMCID: PMC4209256.
- [8] J. Zhang, M. Dong, X. Hu, L. Liu, S. Li, C. Li, L. Yang, Y. Xiao, S. Pang, C. Wang, Prostatic adenocarcinoma presenting with metastases to the testis and epididymis: a case report, *Oncol. Lett.* 11 (1) (2016) 792–794, <https://doi.org/10.3892/ol.2015.3920>. Epub 2015 Nov 16. PMID: 26870285; PMCID: PMC4727079.
- [9] L. Bubendorf, A. Schöpfer, U. Wagner, G. Sauter, H. Moch, N. Willi, T.C. Gasser, M. J. Mihatsch, Metastatic patterns of prostate cancer: an autopsy study of 1,589 patients, *Hum. Pathol.* 31 (5) (2000) 578–583, <https://doi.org/10.1053/hp.2000.6698>. PMID: 10836297.
- [10] S.J. Freedland, P.A. Abrahamsson, Androgen deprivation therapy and side effects: are GnRH antagonists safer? *Asian J. Androl* 23 (1) (2021) 3–10, <https://doi.org/10.4103/aja.aja.22.20>. PMID: 32655041; PMCID: PMC7831824.
- [11] M.D. Hurwitz, Chemotherapy and radiation for prostate cancer, *Transl Androl Urol.* 7 (3) (2018) 390–398, <https://doi.org/10.21037/tau.2018.03.07>. PMID: 30050799; PMCID: PMC6043747.
- [12] A. Bleyer, F. Spreafico, R. Barr, Prostate cancer in young men: an emerging young adult and older adolescent challenge, *Cancer* 126 (1) (2020) 46–57, <https://doi.org/10.1002/ncr.32498>. Epub 2019 Sep 25 PMID: 31553489.
- [13] S. Hussein, S. Satturwar, T. Van der Kwast, Young-age prostate cancer, *J. Clin. Pathol.* 68 (7) (2015) 511–515, <https://doi.org/10.1136/jclinpath-2015-202993>. Epub 2015 Apr 2 PMID: 25837493.