

Case Report

***Salmonella paratyphi* A: A rare cause of infective spondylitis and psoas abscess.**

KA. Kumara<sup>1</sup>, T Kumanan<sup>1</sup>, G Selvaratnam<sup>1</sup>

*Sri Lankan Journal of Infectious Diseases* 2013 Vol.3(1);45-49

DOI: <http://dx.doi.org/10.4038/sljid.v3i1.4530>

Key words: *Salmonella paratyphi* A; septicaemia; fever; psoas abscess; infective spondylitis.

**Abstract**

Invasive salmonellosis is severe and can be life threatening. This is confounded by the emergence of antibacterial resistance - particularly multidrug resistant strains among salmonellae. Primary bone and joint infections due to salmonellae account for less than 1% of all salmonella infections and most of the isolates were *Salmonella typhi* and classically reported in patients with sickle cell disease. This is a case report of a previously undiagnosed type 2 diabetic patient admitted with sepsis who had infective spondylitis involving 1<sup>st</sup> to 4<sup>th</sup> lumbar vertebrae and a right psoas abscess due to *S.paratyphi* A.

**Case report**

A 60 year old female from Jaffna presented to the General Hospital (Teaching) Jaffna with a complaint of fever with chills and rigors, dysuria and back pain of 10 days duration and shortness of breath at rest with chest pain since morning on the day of admission. She had no recent history of diarrhoea.

Her past medical history revealed that she had undergone total abdominal hysterectomy and bilateral salpingo-oophorectomy for an ovarian malignancy followed by chemotherapy in 1971, para-umbilical herniotomy and repair in 2002, and had isolated systolic hypertension for the last two years. She was neither a diagnosed diabetic nor a patient with sickle cell anaemia

On examination she was tachypnoeic, febrile and looked ill. Her pulse rate was 120 beats per minute, with a normal jugular venous pulse and blood pressure. She had bilateral fine basal crepitations over the posterior lung fields. She had no neck stiffness or lumbar vertebral tenderness. Her oxygen saturation on pulse oximetry was 87% on room air.

---

<sup>1</sup>University Medical Unit, General Hospital (Teaching) Jaffna, Sri Lanka.

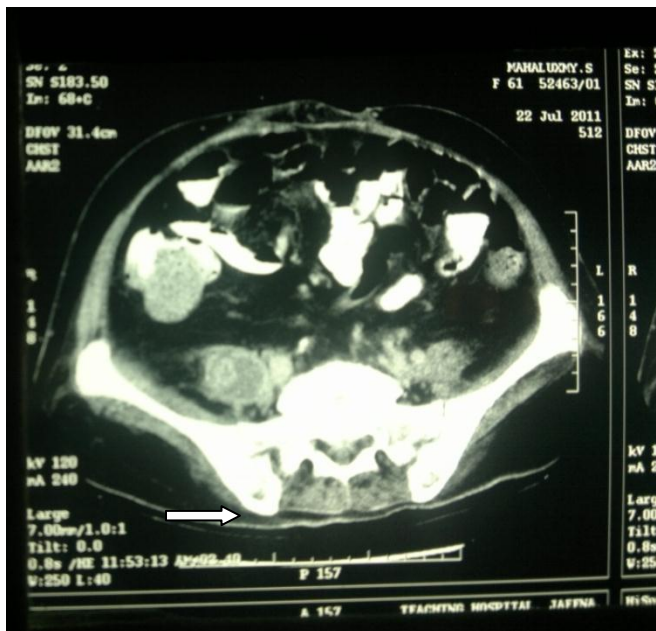Her initial blood investigations revealed a high erythrocyte sedimentation rate, normochromic, normocytic anaemia with rouleaux formation, a severe thrombocytopenia and a polymorphonuclear leukocytosis with total white cell count of 13,000/mm<sup>3</sup>. She was also found to be a type 2 diabetic patient.

Intravenous ceftriaxone was started empirically awaiting blood culture results. In spite of the prompt administration of antibiotics, by day three she was confused and hypotensive with signs of early septic shock. By day five, she had bleeding from puncture sites due to coagulopathy. She also had oliguria and deteriorating renal function.

To our surprise, her blood culture turned out to be positive for *Salmonella paratyphi* A. The isolate was sensitive to amikacin, gentamicin, piperacillin and meropenem and the antibiotic regimen was changed to intravenous amikacin and ciprofloxacin. Levofloxacin was added later. Although she recovered from acute sepsis, high fever spikes continued for nearly two months which warranted further investigations.

Contrast CT thorax and abdomen was performed which revealed an enlarged right psoas with a hypodense area within it indicating a right psoas abscess (Figure 1).

**Figure 1. Contrast CT abdomen showing right psoas abscess**



15 cc of pus were drained via the retroperitoneal approach. Histology of the abscess wall was confirmed by biopsy. “Coliforms” which were not identified further due to resource constraints were isolated from the pus with a similar sensitivity pattern to the blood culture isolate of *S paratyphi* previously isolated. We therefore made a presumptive diagnosis of psoas abscess due to *Salmonella paratyphi* A.

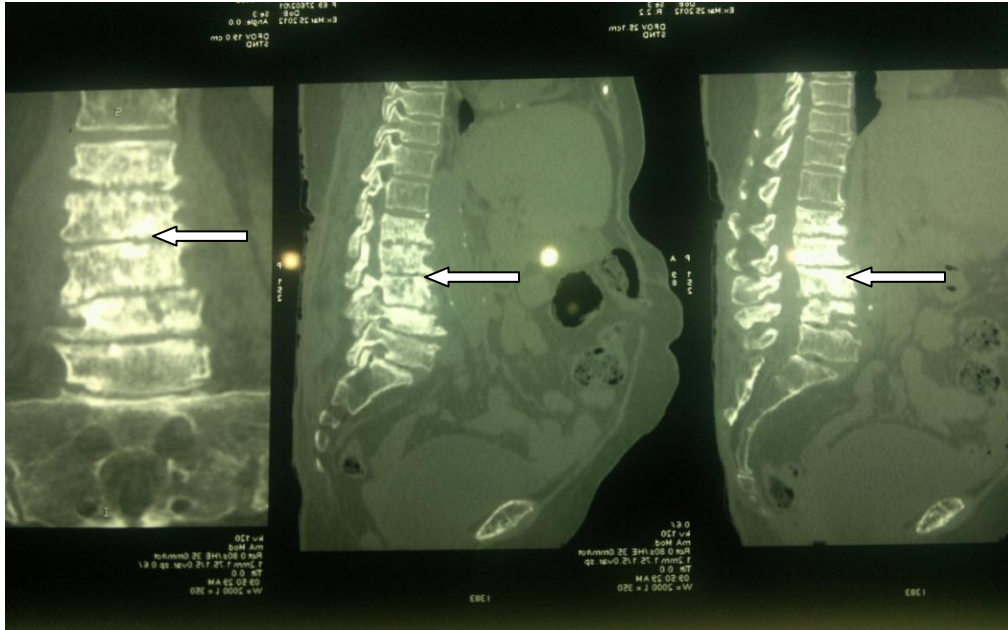
Intravenous amikacin and ciprofloxacin were continued and oral levofloxacin was added. Intravenous treatment was continued for nearly a month. She had a good clinical response and inflammatory markers came down. She was discharged

with oral co-trimoxazole for three more weeks.

Seven months later, she again presented with a complaint of an episode of diarrhea, fever and worsening of back pain and a repeat blood culture re-isolated *Salmonella paratyphi* A with a similar sensitivity pattern. Contrast CT abdomen was repeated which showed sclerosis of the first to fourth lumbar vertebrae and erosions and osteolysis of the inferior half of the vertebrae which was in favor of infective spondylitis (figure 2). It also showed a small left psoas abscess.

She made a good clinical recovery on 3 weeks of ciprofloxacin and cotrimoxazole. She was discharged on oral co-trimoxazole for three more weeks.

**Figure 2. Contrast CT showing sclerosis of whole vertebrae involving L<sub>1</sub>- L<sub>4</sub> and osteolysis and erosions of anterior half of L<sub>3</sub>- L<sub>4</sub> vertebral bodies.**



## Discussion

*Salmonella paratyphi*, a gram negative bacillus, is one of the three main causative agents of enteric fever. After entering the body via food or water, bacteria overcome gastric defenses and penetrate the epithelial cells of the gut where they are phagocytosed by macrophages and disseminate throughout the reticuloendothelial system causing protean clinical manifestations. In developed countries, the most common presentation of salmonellosis is mild to moderate gastroenteritis, whereas in developing countries, particularly in the Indian subcontinent, Africa and South East Asia, the most common presentation is severe gastroenteritis often complicated by septicemia.<sup>1</sup> Although in the past, paratyphoid fever was believed to be a milder disease, recently it has been shown that typhoid and paratyphoid fevers are clinically indistinguishable and paratyphoid fever has a greater complication rate.<sup>1</sup> Currently available typhoid vaccines do not protect against *S paratyphi* though Ty21a oral typhoid vaccine confers significant protection against paratyphoid B but not paratyphoid A disease.<sup>2,3</sup>

According to a surveillance conducted in India, Indonesia, Pakistan and China, enteric fever is more frequently caused by *S paratyphi* than *S typhi*.<sup>4</sup> *S paratyphi* is also capable of causing serious and often life threatening infections like infective endocarditis, pericarditis, sino-venous thrombosis, osteomyelitis, meningitis and bone marrow infiltration. There are anecdotal case reports in the literature of abscesses caused by *S paratyphi*, including renal abscess.<sup>5</sup>

However, psoas muscle abscess is a rare clinical condition with a vague clinical presentation and fever, loin pain and limitation of hip movement may not be found in all patients. Psoas abscess may be primary or secondary. Primary psoas abscess is caused by haematogenous or lymphatic dissemination and *Staphylococcus aureus* is the pathogen in 80% cases. Other organisms include streptococci, *E coli*, serratia spp and pseudomonas spp<sup>6</sup>. This type is mainly seen in immunocompromised patients such as diabetics and alcoholics. The secondary type occurs as a result of local extension, mainly from spinal pathology or intraperitoneal inflammation, and is responsible for 70% of psoas abscesses. Pathogens include *E coli*, Klebsiella sp, Proteus spp and tuberculosis of the spine.

Although rare, spondylodiscitis is the main manifestation of haematogenous osteomyelitis in patients over 50 years. A wide range of organisms have been associated with spondylodiscitis and include *S aureus* accounting for half of non tuberculous cases followed by enterobacteriaceae, *Pseudomonas aeruginosa* and viridans as well as  $\beta$  haemolytic streptococci.<sup>7</sup>

In pyogenic spondylitis, empirical antibiotics comprising the penicillins or third generation cephalosporins should be used. Clindamycin, vancomycin, quinolones and cotrimoxazole also have good bone penetration properties and should be considered, especially for patients sensitive to beta lactam antibiotics. The choice of antibiotics is adjusted according to the subsequent bacterial culture results. Optimal duration of antibiotic therapy is not well defined, with several studies recommending six to eight weeks of intravenous therapy and others recommending only four weeks.<sup>8</sup> *S paratyphi* has shown high degree of susceptibility to ciprofloxacin and amikacin in vitro, while resistance to third generation cephalosporins was observed in about 3-6%.<sup>9</sup> Surgical treatment is absolutely indicated in patients with spinal cord compression or cauda equina compression with progressive neurological deficit. With appropriate treatment, prognosis is generally good with a better prognosis in patients with primary psoas abscess.<sup>10</sup>

## References

1. John Threfall E. Salmonella. In: Peter Borriello, Patrick R Murray, Guido Funke(eds). *Topley & Wilson's Microbiology and Microbial Infections-Bacteriology* (10<sup>th</sup> ed). vol. 2. London: Hodder Arnold, 2005: pp1390-1427.
2. RezwanulWahib, Raphael Simon, Shah J. Zafar et al. Live oral typhoid vaccine Ty21a induces cross- reactive humoral immune response against *Salmonella enteritica* Serovar *paratyphi* A and *S. paratyphi* B in Humans. *Clinical Vaccine and Immunology*. 2012; **19**(6):825-834. <http://dx.doi.org/10.1128/CVI.00058-12>
3. Myron M. Levine, Catterine Ferrencio, Robert E. Black, Rosanna Lagos. Ty21a live oral typhoid vaccine and prevention of paratyphoid fever caused by *Salmonella enteric* serovar *paratyphi* B. *Clinical Infectious Diseases*. 2007; **45**:524-528 [.http://dx.doi.org/10.1086/518141](http://dx.doi.org/10.1086/518141)
4. R. Leon Ochiai, Xuan Yi Wang, Lovenz Von Seidlein, Jin Yang, Sujit K.Bhatthachrya, et al. *Salmonella paratyphi* A. Rate, Asia. *Emerging Infectious Diseases* 2005; **11**(11):1764-1766.<http://dx.doi.org/10.3201/eid1111.050168>
5. D'cruz S, Kochhar S, Chauhan S, Gupta V. Isolation of *Salmonella paratyphi* A from renal abscess. *Indian Journal of Pathology and Microbiology* 2009; **52**:117-119. <http://dx.doi.org/10.4103/0377-4929.44996>

6. Benan M Dala-Ali, Mary- Anne Lloyd, Satish B Janipireddy, Henry D Atkinson. A case report of a septic hip secondary to a psoas abscess. *Journal of Orthopaedic Surgery and Research*. 2010; **5**:70. *No doi*
7. Theodore Goulioris, Sani H. Aliyu, Nicholas M. Brown. Spondylodiscitis; Update on diagnosis and management. *Journal of Antimicrobial Chemotherapy*. 2010; **65** suppl.3iii 11-24. *doi: 10.1093/jac/dkq303*
8. W.Y Cheung, Keith D. K. Luk. Pyogenic Spondylitis. *International Orthopedics*. 2012; **36**(2): 397-404. <http://dx.doi.org/10.1007/s00264-011-1384-6>
9. S.S. Bhattacharry, Usha Das, B. K. Choudhury. Occurrence & antibiogram of *Salmonella typhi* & *S. paratyphi* A isolated from Rourklera, Orissa. *Indian journal of Medical Research*. 2011; **133**(4):431-433. *No doi*
10. Mohamed Nabil Y. M. Riyad, MohamedAlaaSallam, Ali Nur. , Pyogenic psoas abscess: Discussion of its epidemiology, etiology, bacteriology, diagnosis, treatment and prognosis-case report. *Kuwait Medical Journal* 2003; **35**(1):44-47. *No doi*