

CASE SERIES OF KARAM (KSHARA / CORROSIVE GAUZE) APPLICATION ON CHRONIC ULCERS

¹Anpuchelvy.S, ²G. Sritharan, ³S. Ganesan

¹Unit of Siddha medicine, University of Jaffna, ²Herbal Health Care Centre,

³Jaffna Municipal Council Siddha Dispensary,

Sri Lanka

ABSTRACT

Karam acts as natural chemical cauterization and removes the debris from the wound. Among all the yantrams, upayantrams, sastrams, anusastrams (Instruments) and medicines, the karam has the supreme action, because it is most effective and acts immediately. There are many diseases which are not curable with medicine or drugs or are not so much effectively treated such as skin diseases, some allergic condition, Bhagandram (Fistula in ano), Nadi Viranam (Sinuses), Arbuda (Cancer), Moolam (piles), Dustra Viranam (Chronic or non-healing ulcers), warts, melanomas, external abscess, diseases of mouth, some tumor of oral cavity. This diseased portion should be removed or killed, but it is observed that many time drugs fail to work. Surgery is always feared by even those who advocate it. Many times, patients are physically or mentally not fit to undergo surgical operation. Under such condition the alternative measure for advancing the result of surgery is always welcomed. During pre-anesthetic age such alternative procedure was one of the main armamentaria for surgery and it was used in the place of surgery under certain conditions, among such para surgical measures. Karam occupied a prominent place as armamentarium tool of surgery in the ancient era. The external application of karam is used in various diseases, further it can bring about the same result as a surgical operation without its pain agony,

modifying tissue by less degree may give rise to less effusion of blood and less agony than operation. Karam can also be used in the dangerous condition of disease. Karam are more effective than other methods of treatment because they can be administered both internally as paneeyam karam and externally as pratisaraneeya karam. Karam is a single drug, it acts on all the three dosha. The great Siddha sage “Akasthiyar” narrated in kara techniques for the wound healing. Several corrosive gauzes (Karam) are named based on its colour. Thus green, yellow, black and blue corrosive plasters were mentioned in Siddha Medicine for effective wound healing.

Key Words: Bhagandram, Arbuda, Karam

INDRODUCTION

Karam therapy is a Siddha, Ayurveda para surgical technique commonly used to cure anal disease. In this technique a specially prepared Medicated thread known as “Karaseelai” (Medicated Alkaline thread) is used to cure the diseases [1]. Karam acts as a Herbo-mineral chemical cauterization and removes the debris from the body. Among all the yantrams, upayantrams, sastrams, anusastrams (Instruments) and medicines the karam has the supreme action, as it is most effective and acts immediately [2]. There are many diseases which are not

curable with medicine or drugs are not so much effectively treat such as skin diseases, some allergic condition, Bhagandram (Fistula in ano), Nadi Viranam (Sinuses), Arbuda (Cancer), Moolam (piles), Dustra Viranam (chronic or non-healing ulcers), warts, melanomas, external abscess, diseases of mouth, some tumor of oral cavity [3]. These are notorious diseases where use of medicine as well as performing surgery also are difficult and has a lot of complication like – infection, disfigurement, difficulty to approach etc. [4]. The diseased portion should be removed or killed but it is observed that the drug fails to work. Surgery is always feared by those who advocate it [5]. Many times, patients are physically or mentally not fit to undergo surgical operation. Under such condition the alternative measure for advancing the result of surgery is always welcomed [6]. During pre-anesthetic age such alternative procedure was one of the main armamentaria for surgery and it was used in the place of surgery under certain conditions. Among such Para surgical measure, karam occupied a prominent place as armamentarium tool of surgical in the ancient era [7]. The external application of karam are used in various diseases, further it can bring about the same result as a surgical operation without its pain agony, mortifying tissue by less degree may give rise to less effusion of blood and less agony than operation [8]. Its use is not confined to surgical disease only or local applications, but also advantage of application of karam can applied to the people of delicate temperament and age. Karam can also be used even in the dangerous condition of a disease. Karam are more effective than other methods of treatment. Because they can be administered both internally as paneeyam karam and externally as prataraneeya karam[9]. Karam is a single drug, it acts on all the three dosha. The great Siddha sage “Akasthiyar” narrated in

kara techniques for the wound healing [10].

Objectives

The study was accomplished to perceive the clinical efficacy and safety of Karam (Medicated Herbo-mineral Corrosive Mixture) for the management of diabetic chronic ulcers and fistula.

Case Number- 1 A male patient aged 45 years presented with complains of nonhealing wounds over the left foot (medial aspect) (Figure-II) for a period two months. On query, patient was found to be a case of controlled diabetes for three years and become uncontrolled last six to eight months. He was on antidiabetic treatment on hypoglycemic from a renowned diabetologist from nearby allopathic hospital and his blood glucose levels become normal limits. But from last two months he developed non- healing wounds over left foot. He took treatment for the same from modern medicine surgeons but prognosis become poor and advised to undergo left foot amputation to avoid further complications. After the careful clinical examination, wound was found irregular in shape with unhealthy granulation tissue and the surrounding areas of wound shows inflammatory changes with unpleasant foul-smelling & watery discharges. Therefor decided to treat the impending diabetic condition and prevent the foot from amputation which become as a major challenge.

Wound management

At first, the wound was cleaned with Tripala decoction (herbal antiseptic lotion) to prevent the growth of harmful microorganisms. A special traditional wound healing ‘Karam’ technique was employed to treat this wound and Medicated Herbo-mineral Corrosive Mixture Gause known as “Pachakarasealai” was used (Figure III). Pacha karasealai is prepared by repeatedly

soaking sterilized gauze in a solution of Pacha karam (Medicated Herbo-mineral Corrosive Mixture) “Pachal karam” also applied over the adjoining wound and bandaging is done.

Pacha Karacheelai (Green Corrosive Gauze) in the Treatment of Chronic Ulcer

Several corrosive gauzes are named based on their colour. Thus green, yellow, black and blue corrosive plasters are used in Siddha Medicine. Similarly corrosive liquids are named according to their colour which are used to clean ulcers. All of them are indicated for external use in chronic ulcers. Meanwhile no research reports were found regarding their use in actual practice [11].

Ingredients of Pachai karam (Reference Akathiyar rana nool -1975)

- Curcuma longa Powder
- Yellow oxide of Arsenic (synthetic)
- Yellow Arsenic Trisulphide
- Silver Sulphide
- Galena Sulphide (Lead ore)

each of them same amount was taken.

All ingredients total weight amount of blue mixed and grinding as powder forms and mixed sterile water or Glycerin and mixed semisolid liquid form (Figure -I).



Fig-1 Pacha karacheelai (Green corrosive gauze)

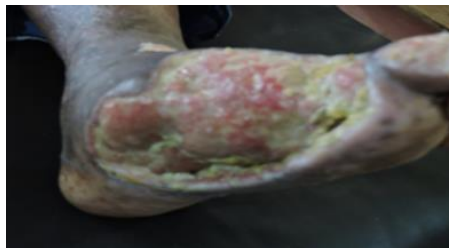

Fig-11 – Chronic Leg ulcer



Fig-111 - Pacha karacheelai (Green corrosive gauze) application on chronic leg ulcer

Case Number- 2: A female patient aged 65 years presented with complaints of ulceration right side of the foot, blackish discoloration, and oozing of serous fluid with a foul smell for the last three months. The lesion started six months before with bluish discoloration on the dorsum of the foot then it gets reddish with a blister, then the pus oozes from the wound and it gradually spread over the foot skin with itching, serious watery foul smell secretion. The patient obtained surgical management at an allopathic hospital. Thereafter patient got mild symptomatic relief but it relapses repeatedly. Consequently, the patient seeks Siddha Ayurveda treatment and her health problem was diagnosed as a chronic diabetic wound.

On physical examination

The general condition of the patient was good; her pulse was 82/ min, regular; BP was 120 / 70 mm Hg, respiratory rate was 20 /min regular, with a history of diabetes mellitus with a Random Blood Sugar level of 123mg/dl.

Wound management

At first, the wound was cleaned with Tripala decoction (herbal antiseptic lotion) to prevent the growth of harmful microorganisms and a fistula was identified. A special traditional wound healing 'Kshara' technique was employed to treat this wound fistula and Medicated thread known as "Manjal karasealai" (corrosive gauze) was used (Figures IV and V). Manjal karasealai is prepared by repeatedly soaking sterilized gauze in a solution of Manjal karam (medicated Herbo-Mineral Corrosive mixture) "Manjal karam" also applied over the adjoining wound and bandaging is done.

Manjal Kara Cheelai (Yellow Corrosive Gauze) Application on Diabetic Ulcer

Application of corrosive drugs (karam) to heal chronic ulcers is one among the 32 forms of external drugs in Siddha Medicine. Agathiyar Rana Vaithiyam, Agathiyar Rana Nool are some of the ancient texts of Siddha Medicine, giving details of the preparation of corrosive gauze [12].

Ingredients of Manjal karam (Reference Akathiyar rana nool -1975)

- Curcuma longa Powder
- Yellow oxide of Arsenic (synthetic)
- Yellow Arsenic Trisulphide
- Galena Sulphide (Lead ore)
- Lime stone.
- Sulphate of zinc
- Resin of Shorea robusta

each of the ingredients same amount was taken.

Total weight amount of white cloth was taken. Ingredients were mixed and grind to powder form. Then mixed with sterile water or Glycerin to get semisolid liquid foam. (Figure-v).



Fig-IV- Manjal karacheelai (Yellow corrosive gauze)

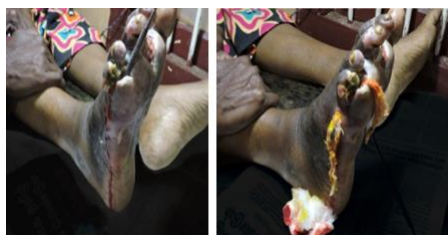

Fig-V &VI Probing of the Manjal karacheelai -Fistula of the wound

The above said gauze was used by the author to treat a patient with chronic diabetic leg ulcer. This 61 year female diabetes patient underwent allopathic treatment & surgery for chronic leg ulcer, end up with relapses and non-cure. Then she seeks Siddha treatment and it was done to cure leg ulcer using yellow corrosive gauze every other day for 10 weeks. At the end of treatment patient had complete relief by healed leg ulcer.

Case Number -3: Male patient aged 30 years, already taken allopathic treatment & surgical managements, resulted to recurrences and grief. Then he decided to get native treatment of Siddha Medicine. He presented with the complaints of pain in the anal area, swelling and discharge of pus and mild irritation at that area. Patient underwent pre-clinical assessments like

per rectum examination by probing method and diagnosed as Fistula- in – gluteal region. Afterwards twice a week, yellow corrosive gauze was inserted into the fistula by using probs. This patient had complete relief after 2 months of such treatments.

Post-wound management

The wound was cleaned and karasealai was changed every other day. Random blood sugar levels were also monitored and maintained below 150mg/dl.

Details of oral drugs

Initially, oral medication was given for 7 days to the patient for Pachana. Panchatheppakni churnam 3g with hot water bd. Kaishoor Guggulu 2 tablets (500 mg each tablet) tds, 1 h after food, Arogyavardhani vati 2 tablet (250mg each tablet) tds, Thripala churnam 4 g bd with hot water.

In the second week

Continued with initial medication with wound healing Churnam 3g bd with hot water. Sutharsana, tab 2 bd, with hot water, Seenthil kudineer 60 ml bd 1 hour before food, and Kadukai chunam 3g with hot water at bedtime. All these medications were continued for two months. The patient was advised to continue the allopathic treatment (diabetic) and dietary advice to maintain a random blood sugar level below 150 mg/dl.




Fig-VII Manjal karacheelai application in Fistula at the gluteal region

DISCUSSION

Karam remains in direct contact with fistula tracts, therefore acts directly on the diseased area. Karam dissolves the tough fibrous tissue & chemically cures all the infection out from the tract and thereby allowing the fistulous tract to collapse & heal [13] Karam performs cutting of the Fistula tract because of the mechanical pressure of tightening the thread at each seating [14] . This action allows slow cutting of the Fistula tract & simultaneously healing the wound.

Benefits of this therapy

It is an outpatient treatment

Performed mostly under local anesthesia.

Only 30-45 minutes is required for the primary procedure.

Hospital stay is usually not required.

Minimal bed rest is required after the procedure.

Patient can resume his / her daily routine work within 3 to 5 days.

The recurrence rate is very less after Kara therapy.

The most important benefit of Kara therapy over major surgeries is the muscles that supports the anus and helps in controlling the bowel movements are not possible of anal incontinence (loss of power to hold stools) [15] Karam (Kshara) penetrating property (teeksshana), hot potency (Ushna) and fire like qualities is similar to fire in action. Then how does it cure the mitigating effect of kshara. The Karacheelai application expulses the impure debris' and vitiated Doshas (toxins and unwanted metabolites are removed). It facilitates fresh blood supply and promotes formation of new tissues [17]. Karam has rich source of poly phenolic compounds [18] that empower with broad spectrum antimicrobial potential. It has been reported highly effective against various pathogenic and nonpathogenic

bacterial strains [19] Karam also has shown broad spectrum antimicrobial activity against some resistant bacterial isolated from the human secretion [20].

CONCLUSION

The Karacheelai application expulses the impure debris' and vitiated Doshas (toxins and unwanted metabolites are removed). It facilitates fresh blood supply and promotes formation of new tissues (ropana). Hence it helps in simultaneous cleansing and healing of infected tissues. Even though the fistula- in. ano and chronic diabetic wound fistula were very difficult to treat. But fistula –in- anus and chronic diabetic wound fistula were completely healed within 2 months by Kara application. This Kara application proves to be effective, time saving, affordable, and acceptable treatment on fistula- in –ano and chronic diabetic wound fistula. It can be managed with herbo-mineral application of Karacheelai.

Consent For Publication: Not applicable
Availability of Data and Materials: The author confirms that the data supporting the findings of this research are available within the article.
Conflict of Interest: Authors have no conflict of interest.

REFERANCES

Lall S.P. *Ranavaithiya Sinthamany 2nd Edition,1935) Chennai.*
Eisenhammer S: *The anorectal fistulous abscess and fistula.Dis Colon Rectum, 9: 91-106, 266.*
Marks CG & Ritchire JK (1977). *Anal fistulas at St Marks's Hospital. Br.J Surg 64:84-91.*
Henrichsen S, & Christiansen J (1986) *Incidence of fistula –in –ano complicating anorectal sepsis: a prospective study Br j Surg. 73: 371-372.*

Marks CG & Ritchire JK (1977). *Anal fistulas at St Marks's Hospital. Br.J Surg 64:84-91*
Grace RH, Harpet IA & Thompson RG (1982) *Anorectal sepsis: microbiology in relation to fistula-in- ano. BrJ Surg 69: 401- 403.*
Lele, R.D. *Ayurveda and Modern Medicine, Bhrateeya vidya Bhavan, Bombay, 1st edition, 1986.*
Bailey & Love, *Short practice of surgery, international student edition, London 19th edition. 1998.*
Acharya Bhavamishre, Bhava Prakasha, *Transalated by Srikantha Murthy,Krishna DasAcademy, Varanasi,Vol:1, 2nd edition 2001.*
Agathiyar Rana Nool, *2nd Edition, (1935) Chennai.*
Joseph Thas J , *Pachai Kara Cheelai in treatment of chronic ulcers. 2nd National conference on Siddha Medicine for All Ages 2002. Tirunelvely.*
Joseph Thas J, *Manjal Kara Cheelai in treatment of chronic ulcers. 2nd National conference on Siddha Medicine for All Ages 2002. Tirunelvely.*
Agathiyar Rana Vaithiyam, *2nd Edition, (1935) Chennai.*
Thomson JPS & Parks AG (1979).*A nal abscess and fistulas Br.J Hosp Med 21: 413- 425.*
Abcarian H, Dodi G, Girona J et al. *Fistula in ano. I nt J Color Dis 1987; 2: 51-71.*
Syed Mohammed Jalaludheen. *Outline of Salyatantra. 2016. Varnasi. Akumar and M.V.V.Prasad Anti microbial activity of Tripala churnam Argvaidyan Vol 18 (2) p 109-111 2003.*
Naik G.H, I.Priyadarsiny, and H.Mohan *Free redical scavenging reaction and phytochemical analysis of Kshara an ayurvedic formulation current science Vol 90 (8) p 1100-1105.*
Nilesh Gupta, Jain UK. *Prominent wound healing properties of indigenous medicines. Journal of Natural Pharmaceuticals. 2010.*
Mahalashimi K,J. Pirabakaran and Sukumaran V.C *Antibacterial activity of Kshara and curcumin on enterococci faecalis Biomedicine Vol26 (3) p 43 - 46 2006.*