



Case report

A case report: A rare case of icteric variant of Stauffer's syndrome

P. Abiharan^a, B. Balagobi^{b,*}, S. Gobishangar^b, R. Senthuran^b, T. Thulasi^c^a University Surgical Unit, Teaching Hospital Jaffna, Sri Lanka^b Department of Surgery, Faculty of Medicine, University of Jaffna, Sri Lanka^c Department of Radiology, Teaching Hospital Jaffna, Sri Lanka

ARTICLE INFO

Keywords:

Stauffer's syndrome
Paraneoplastic syndrome
Renal carcinoma
Cholestatic jaundice
Bosniak cysts

ABSTRACT

Introduction: Stauffer's syndrome is a rare paraneoplastic non metastatic hepatic dysfunction related to renal cell carcinoma. It is characterized by elevated alkaline phosphatase, erythrocyte sedimentation rate, a-2-globulin, y-glutamyl transferase, thrombocytosis, prolongation of prothrombin time and hepatosplenomegaly, in the absence of hepatic metastasis. A rare variant of it with cholestatic jaundice is described in four cases so far in literature.

Clinical presentation: We present a case of a patient presented with features of cholestatic jaundice who was found to have a left sided renal cell carcinoma in the work up.

Discussion: This case illustrates the importance of considering paraneoplastic syndromes in mind when working up for patients presenting with hepatic dysfunctions without identifiable causes.

Conclusion: This may result in early identification and intervention which will result in better outcome and prolong survival rate.

1. Introduction

Paraneoplastic syndromes are symptom and sign complexes occurring in patients with malignancies that cannot be attributed to local or distant spread of the tumor or hormones that are secreted by the tumor and are indigenous to the tissue of origin of the tumor. Renal cell carcinoma (RCC) is unique among genitourinary malignancies in that around one out of three patients have signs and symptoms of paraneoplastic syndrome [1]. Those of RCC include fever, polycythemia, hypercalcemia, hypertension, Cushing syndrome, feminization or masculinization, etc. [2]. Stauffer's syndrome is one of the rare paraneoplastic syndromes associated with RCC, characterized by elevated alkaline phosphatase, erythrocyte sedimentation rate, a-2-globulin, y-glutamyl transferase, thrombocytosis, prolongation of prothrombin time, and hepatosplenomegaly in the absence of hepatic metastasis [3]. The presence of jaundice is not the usual phenomenon of this non-metastatic hepatic dysfunction, but very few cases have been observed in the past. This is a case report of a patient who presented with pruritus, cholestatic jaundice, and a Bosniak type IV cyst in imaging and was drafted in line with the SCARE 2020 criteria [4].

2. Case presentation

A 68-year-old previously diagnosed patient with hypertension and type 2 diabetes mellitus was admitted to the hospital with a two-week history of generalized pruritus, yellow discoloration of the eyes, pale stools, dark urine, and an on-and-off mild fever. His past surgical history was unremarkable. He denied using alcohol, tobacco, or any drugs that were not prescribed, and he had no risk factors for viral hepatitis or sexually transmitted diseases. On general examination, he was icteric and had multiple scratch marks; otherwise, he was normal. His abdomen examination had no significant physical findings. On his laboratory test, the full blood count (FBC) parameters, alanine transaminase (ALT), aspartate transaminase (AST), total protein, and prothrombin time were in a normal range. He had elevated alkaline phosphatase, direct and total bilirubin, serum creatinine, and decreased serum albumin (Table 1).

Ultrasonographic study of the abdomen revealed a large mass arising from the interpolar region of the left and multiple gallbladder calculi, but intra- and extra-hepatic ducts were not dilated. The liver and spleen were of normal size and echogenicity, without any evidence for cirrhosis or ascites. An intravenous contrast-enhanced computed tomographic (CT) scan of the chest, abdomen, and pelvis was done, and it revealed a large, well-defined lesion in the interpolar region of the left kidney,

* Corresponding author.

E-mail address: b.balagobi@yahoo.com (B. Balagobi).<https://doi.org/10.1016/j.ijscr.2023.108455>

Received 8 May 2023; Received in revised form 16 June 2023; Accepted 27 June 2023

Available online 1 July 2023

2210-2612/© 2023 The Authors. Published by Elsevier Ltd on behalf of IJS Publishing Group Ltd. This is an open access article under the CC BY-NC-ND license (<http://creativecommons.org/licenses/by-nc-nd/4.0/>).

Table 1

Comparison of pre-operative laboratory parameters with that of post-operative values on post-operative day 10.

Laboratory parameters	Pre-operative values	Post-operative values
Haemoglobin level (g/dL)	9.8	10.5
Leukocytes ($\times 10^3$ U/L)	9.94	9.3
Platelets ($\times 10^3$ U/L)	368	245
Total bilirubin ($\mu\text{mol/L}$)	198.4	30.8
Direct bilirubin ($\mu\text{mol/L}$)	161.4	15
AST (U/L)	38	38
ALT (U/L)	24	24
ALP (U/L)	488	267
Total protein (g/L)	70	72
Albumin (g/L)	23	23
Prothrombin time (s)	14.4	10

predominantly hypo-dense with enhancing linear and nodular soft tissue components and multiple calcifications with a well-defined capsule without adjacent organ infiltration or vascular invasion suggestive of Bosniak type IV and a few sub-centimetre para-aortic and bilateral external iliac lymph nodes (see Fig. 1).

His liver was normal without any evidence of metastasis. His biliary system had uncomplicated gallbladder stones, no stones in the bile duct, and no evidence of biliary dilation. After a meeting with a multidisciplinary team (MDT) with a urologist, radiologist, gastroenterologist, and oncologist, magnetic resonance imaging was performed to characterize the renal tumor as well as to look for evidence of causes for his cholestatic jaundice. His magnetic resonance cholangiopancreatography

(MRCP) was unremarkable, and the histopathologic study of the lesion showed papillary architecture with central foamy macrophages lined by a single layer of basophilic cells suggestive of type 1 papillary renal cell carcinoma (Fig. 2). In the follow-up MDT meeting, it was decided to consider the jaundice a paraneoplastic syndrome and proceed with left radical nephrectomy with curative intent. After a week of pre-operative evaluation and optimization, he underwent a left radical nephrectomy (Fig. 3) by an experienced team consisting of a urologist and a general surgeon without any complications. The lesion was confined to the kidney without any break in the capsule or vascular involvement. His post-operative stay was unremarkable, and his cholestatic symptoms started to improve with an evident drop in his liver biochemistry, as shown in Table 1.

3. Discussion

Renal cell carcinoma, which originates in the renal cortex, accounts for most of the malignant neoplasms of the kidney. RCC can present with a wide variety of symptoms and signs; the most common and classical triad of them is hematuria, flank pain, and abdominal mass. As with advancing imaging technology and frequency, there was an increased rate of detection of a renal neoplasm; therefore, RCC was done incidentally for imaging done for other purposes. The classic diagnostic triad is found in less than 10 % of the cases [5]. The left-sided RCC can also present with a left varicocele in around 11 % of males [6]. They can also present with signs and symptoms due to metastatic effects, among which spread to the lungs, lymph nodes, bones, brain, and liver is most

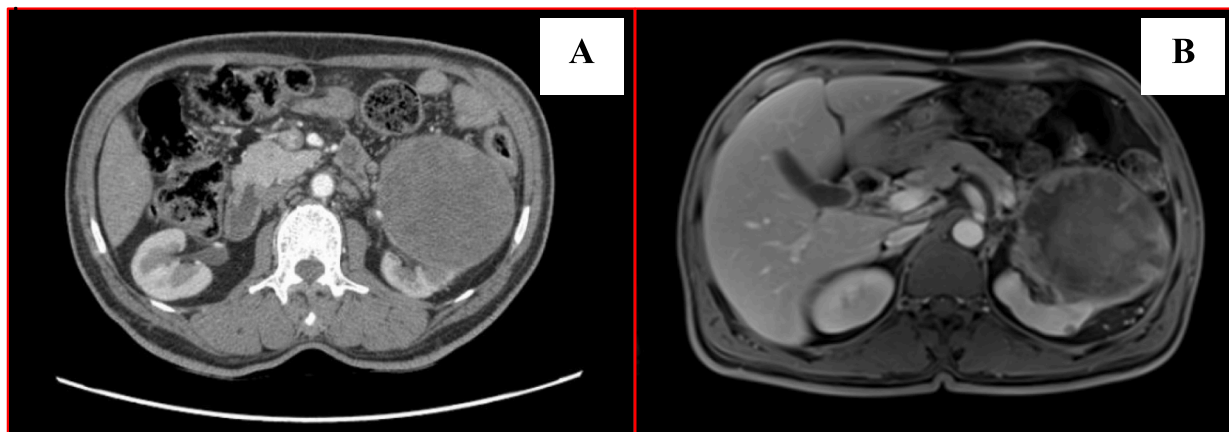


Fig. 1. (A) CT with contrast revealed a large well-defined lesion in inter-polar region of left kidney and (B) MRI indicated the renal lesion with renal cell carcinoma.

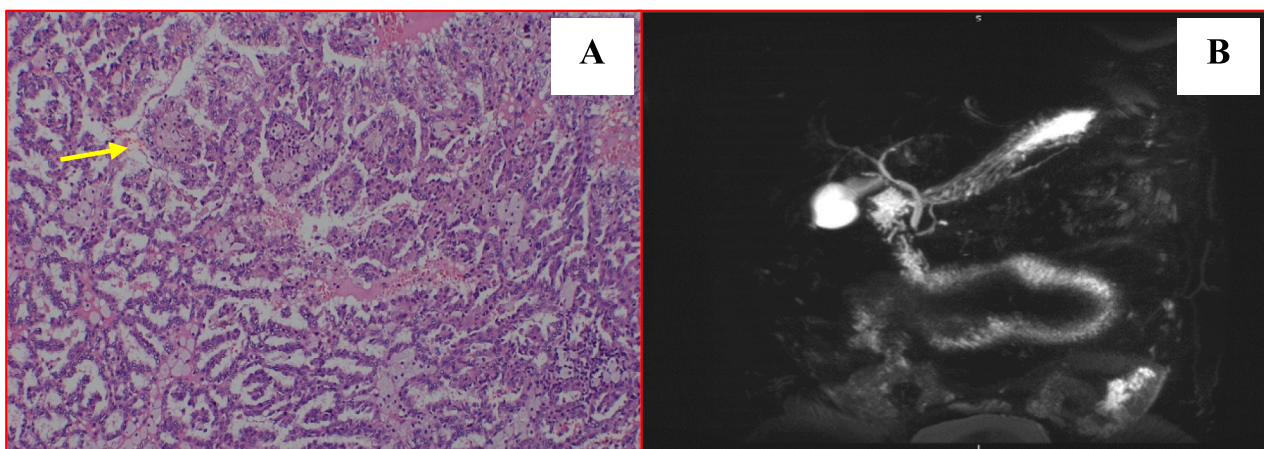


Fig. 2. (A) Unremarkable MRCP (B) central foamy macrophages lined by single layer of basophilic cells suggestive of type 1 papillary renal cell carcinoma.

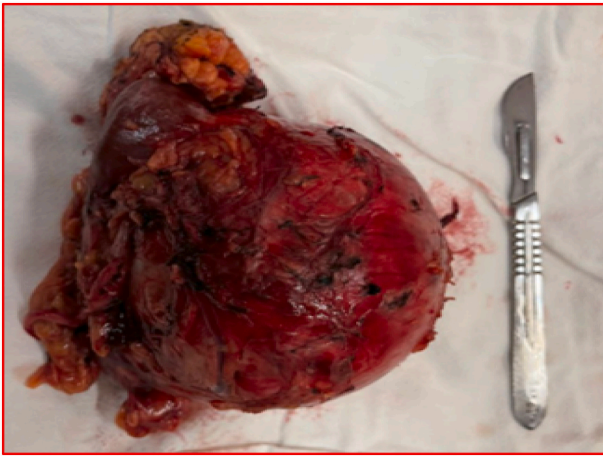


Fig. 3. Showing the resected specimen including the left kidney.

common. It has also been estimated that 20 % of patients with RCC can also present with features due to paraneoplastic syndrome [7]. The paraneoplastic manifestations of RCC include cachexia, fever, hepatic dysfunction, which is non-cholestatic, anemia, polycythemia, amyloidosis, hypercalcemia, and neuromyopathy [8]. Malignancies can cause cholestatic jaundice for a wide variety of reasons, either through obstruction to the biliary system as a direction of invasion of tumors such as pancreatic carcinoma, cholangiocarcinoma, or periampullary carcinoma, or as a result of hepatic metastasis. Non-metastatic nephrogenic hepatic dysfunction syndrome without jaundice has often been described in patients with hypernephroma (Stauffer's syndrome), but paraneoplastic cholestatic jaundice is not well recognized [9]. In our case study the initial presentation was that of obstructive jaundice and no signs or symptoms were attributable to the left side renal tumor. The finding of renal tumor through ultrasonographic study was an actual incidental finding. The cause for the cholestatic jaundice was not established through even advanced imaging like MRI and CECT as well as other above mentioned laboratory tests also the resolution of the sign, symptoms and the return of the liver biochemistries and bilirubin levels following the resection of the left renal tumor confirms that the phenomena is due to paraneoplastic effect of the tumor [10].

4. Conclusion

In a patient present with hepatic dysfunction and cholestatic jaundice without an identifiable cause, after the initial workup and investigation, the paraneoplastic effect of tumors should be kept in mind and investigated accordingly, especially for renal cell carcinoma of the kidney. Early detection and management will lead to better outcomes and a prolonged survival rate.

Ethical approval

Our Institutional Review Board (IRB) does not require ethical approval for reporting individual cases or case series.

Sources of funding

None.

CRediT authorship contribution statement

Study concept – Balagobi B.

Data collection – Abiharan P, Senthuran R and Thulasi T.

Data analysis – Gobishangar S.

Statement of informed consent

Written informed consent was obtained from the patient for publication of this case report and accompanying images. A copy of the written consent is available for review by the Editor-in Chief of this journal on request.

Declaration of competing interest

There is no conflict of interest between the authors as everybody is aware of the work and participated actively and equally.

Acknowledgment

The authors wish to thank, S.Thiruvarangan, Research Assistant who assisted in the manuscript preparation and submission process in the final stage of this article.

References

- [1] Ganesh S. Palapattu, et al., Paraneoplastic syndromes in urologic malignancy: the many faces of renal cell carcinoma, *Reviews in Urology* 4 (4) (2002) 163–170.
- [2] Diana Morla, et al., Stauffer's syndrome variant with cholestatic jaundice: a case report, *Journal of General Internal Medicine* vol. 21 (7) (2006) C11–C13.
- [3] D.G. Skinner, et al., Diagnosis and management of renal cell carcinoma. A clinical and pathologic study of 309 cases, *Cancerol.* 28 (5) (1971) 1165–1177.
- [4] Agha R, A. Franchi, T. Sohrabi, C. Mathew, G. (2020).The SCARE 2020 guideline: updating consensus Surgical Case Report (SCARE) guidelines. *Int. J. Surg.*, 84, 226–230.
- [5] R.S. Pinals, S.M. Krane, Medical aspects of renal carcinoma, *Postgrad. Med. J.* 38 (443) (1962) 507–519.
- [6] P.J. Gold, et al., Paraneoplastic manifestations of renal cell carcinoma, *Semin. Urol. Oncol.* 14 (4) (1996) 216–222.
- [7] Sharma, Neha et al. "Stauffer Syndrome: A Comprehensive Review of the Icteric Variant of the Syndrome." *Cureus* vol. 11,6032.
- [8] A. Romašovs, A. Puķītis, V. Mokricka, E. Frolova, Stauffer's syndrome in patient with metastatic prostate cancer, *Case Reports in Urology* 2019 (2019) 9745301.
- [9] S.P. Dourakis, et al., Cholestatic jaundice as a paraneoplastic manifestation of renal cell carcinoma, *Eur. J. Gastroenterol. Hepatol.* 9 (3) (1997) 311–314.
- [10] N. Assy, et al., Diagnostic approach to patients with cholestatic jaundice, *World J. Gastroenterol.* 5 (3) (1999) 252–262.