

Case Report

Erythropoietin antibody-mediated pure red cell aplasia: a rare cause of anaemia in chronic kidney disease

Piratheepan Navaradnam¹, Thirunavukarasu Kumanan², Thaneshwary Sooriyakumar¹

¹Teaching Hospital, Jaffna, Sri Lanka, ²University of Jaffna, Sri Lanka,

Key words: pure red cell aplasia, erythropoietin, chronic kidney disease, anti-erythropoietin antibody

Corresponding Author: Piratheepan Navaradnam, E-mail:<piratheepan.kajan@gmail.com>  <https://orcid.org/0000-0002-8984-2719>

Received: 28 Jan 2021, Accepted: 23 Apr 2021 2020, Published: 30 Jun 2021

Competing Interests: Authors have declared that no competing interests exist

© *Authors. This is an open-access article distributed under a Creative Commons Attribution-Share Alike 4.0 International License (CC BY-SA 4.0), which permits unrestricted use, distribution, and reproduction in any medium, provided the original author and source are attributed and materials are shared under the same license.*



Introduction

Pure red cell aplasia (PRCA) is a rare form of acquired haematological disorder. Rapid onset normochromic normocytic anaemia, low reticulocyte count and severe hypoplastic erythroid lineage with normal other cell lines in the bone marrow is the classical picture of PRCA [1]. Anaemia in a patient with chronic kidney disease could be due to several factors such as impaired production of erythropoietin, iron deficiency (functional/absolute), Vitamin B12 and folic acid deficiency, suboptimal dialysis or gastrointestinal blood loss [2]. The incidence of erythropoietin antibody-mediated PRCA is 0.02-0.03 per 10000 patient-years [3]. The incidence was noted to be increasing between 1998-2002 [4]. The aetiology of PRCA could be congenital (Diamond Blackfan syndrome) or acquired (including viral infections, lymphoid and plasma cell disorders, autoimmune conditions, pregnancy and certain medications) [5]. Here we report a patient with erythropoietin antibody-induced PRCA.

Case history

A 69-year-old male with type 2 diabetes, hypertension and coronary heart disease was admitted to the medical ward with a history of exertional tiredness. On examination, he was pale. The rest of the systemic examination was unremarkable. A complete blood count revealed a Hb of 7.9g/dl with a normal MCV (81fl) and normal other cell lines. Ultrasound abdomen confirmed chronic kidney disease as evidenced by increased echogenicity of both kidneys. Peripheral blood film showed anaemia of chronic disease with marked rouleaux formation. His ESR was 60 mm/hour. A myeloma workup, including urine for Bence Jones protein from three early morning samples, skeletal survey and serum ionized calcium, were within normal limits. Serum protein electrophoresis was in favour of chronic inflammation. Serum ferritin was high (322ng/ml). On further questioning, he denied a history of per rectal bleeding or melaena. The dietary pattern was of an average Sri Lankan rice-based diabetic diet with good nutritious value. He was

treated with two units of blood and a weekly 4000u s/c erythropoietin injection. Aspirin therapy was withheld and he underwent a gastroduodenoscopy, which was unremarkable. He was reviewed in the medical clinic monthly and his hemoglobin was stable between 9 to 10 g/dl for a period of nine months.

Subsequently, he was admitted to the ward with severe exertional tiredness and chest pain. On physical examination, he was noted to have severe pallor. A vigilant search for an occult bleeding site was sought with upper gastroduodenoscopy and colonoscopy but no identifiable source was found. He was again transfused with 4 units of blood. In the first week of July 2020, he was admitted again with a similar complaint and the Hb was 3.2 g/dl, HCT 10.6%, MCV 86fl and the other cell lines were consistently normal. Reticulocyte count was 0.01%, LDH 212U/l and serum direct and indirect bilirubin were within the normal range. A summary of biochemical results is shown in Table 1.

We proceeded with bone marrow examination (Figure 1) which showed a normocellular marrow with marked erythroid hypoplasia suggestive of pure red cell aplasia (PRCA) and it was suggested to exclude underlying lymphoma / lymphoproliferative disorder or drug-induced aplasia. Contrast-enhanced imaging of the chest, abdomen and pelvis was done with precautionary measures and revealed bilateral perinephric fat stranding in the kidney suggesting pyelonephritis or chronic renal parenchymal disease. However, it failed to show evidence of organomegaly, lymphadenopathy or solid organ malignancy. As a workup to exclude secondary causes of erythroid hypoplasia, ANA, rheumatoid factor, Parvo B19 IgG, EBV IgG, CMV IgG and repeated myeloma screen was done and proved negative. Erythropoietin induced antibodies was thought to be the culprit and withheld and he was commenced on prednisolone 40mg along with azathioprine 50mg daily.

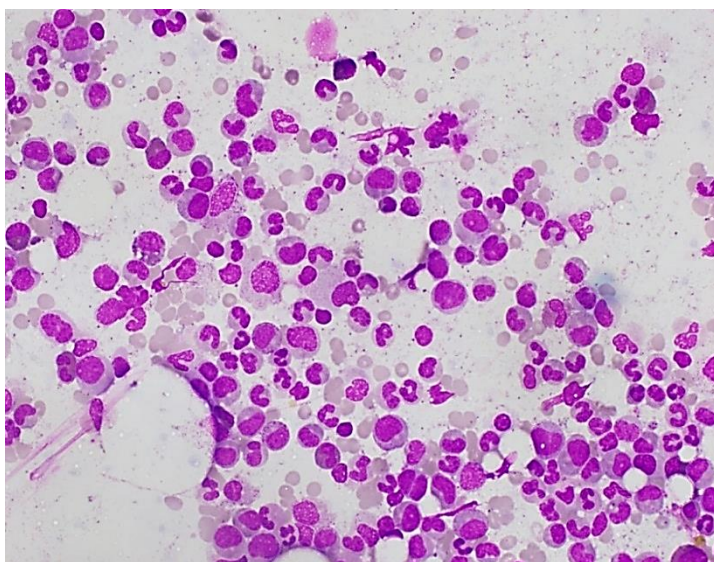


Figure 1: Pure red cell aplasia. Leishman stain × 40 Morphological features in marrow aspiration showing severe erythroid hypoplasia with normocellular granulopoiesis and megakaryopoiesis.

Table 1: The biochemical profile with the course of the illness.

Biochemical investigations	September 2019	June 2020	July 2020
Full blood count			
White cell count (4-10×10 ⁹ /l)	7.09×10 ³	10.1	9.82
Abs.Neutrophils (2-7×10 ⁹ /l)	6.18	9.2	8.83
Abs.Lymphocytes (1-3×10 ⁹ /l)	0.58	0.7	0.81
Abs.Eosinophil(0.04-0.6×10 ⁹ /l)	0.01	0.02	0.05
Abs.Basophil(0.0-0.09 ×10 ⁹ /l)	0.03	0.05	0.06
Haemoglobin (130-170g/l)	79	38	32
HCT(0.40-0.50)	32	24	10.6
MCV (83-101fL)	81	84	86
Red cell count (4.5-5.5×10 ¹² /l)	4.4	3.2	0.4
Platelets (150-410×10 ⁹ /l)	209	221	178
Reticulocyte	2	--	0.01
LDH (U/L)	180	236	212
Inflammatory markers			
ESR (1 st hour)	60	55	48
CRP (0-3.0mg/L)	6	9	12
Renal functions tests			
Blood urea (2.5-6.4 mmol/L)	7	6.8	7.2
Serum Creatinine (62-115µmol/L)	259	235	260
Serum electrolytes			
Serum sodium (135-145 mmol/L)	142	144	148
Serum Pottasium (3.5-5.0 mmol/L)	4.6	4.4	4.2
Serum Calcium (8.6-10.2 mg/dL)	9.9	9.8	10.1
Serum Phophorus (2.6-4.5 mg/dL)	3.8	4.2	4.4
Liver Profile			
Serum AST (0-45 U/L)	32	42	36
Serum ALT (0-35 U/L)	34	40	38
Serum bilirubin (0-17.1µmol/L)	0.6	0.8	0.7
Serum protein (6.4-8.3g/dL)	6.5	6.9	7.1
Serum albumin	4	4	4.1
Serum globulin	2.9	2.9	3
Urine full report			
Protein (+)	+	--	+
Pus cells (/HPF)	10-15	--	10-12
Red cells (/HPF)	1-3	--	3-5
Active sediment (+)	--	--	--
Serum ferritin	322ng/dl	392ng/ml	600

Discussion

The mechanism of drug-induced PRCA is mostly unexplained in the medical literature but erythropoietin induced PRCA is well explained by autoimmunity or antibody-mediated mechanisms [2]. Five main factors determine the pathogenesis of erythropoietin

mediated PRCA. The *first* factor is patient-related such as genetics, age, sex, comorbid condition and medication [4]. HLA DR B19, male sex, age>60 years are high risk. The *second* factor is the route of administration; a subcutaneous injection is more immunogenic than intravenous injection because antigen-presenting cells are more concentrated in the skin and erythropoietin is available for a long duration subcutaneously [6]. Duration of treatment would be the *third* factor [6]. If the patient is treated with erythropoietin for 3 to 6 or more months, the risk of developing an anti erythropoietin antibody is higher. Breaking the cold chain with improper handling or self-handling and product-related factors are the 4th and 5th factors respectively [6]. In this particular patient, age > 69 years, male sex and subcutaneous injection given for more than 9 months were risk factors in favor of erythropoietin induced antibody mediated PRCA.

Three assay types are available to identify anti-erythropoietin antibodies, radioimmunoprecipitation assay, ELISA, and surface plasmon resonance procedure [5]. A major limitation of this report was our inability to demonstrate such evidence due to the unavailability of such high-profile investigations in Sri Lanka.

In this patient, the diagnosis of erythropoietin induced red cell aplasia could be convincingly made based on the following features. A typical presentation with a rapid drop in haemoglobin, becoming transfusion-dependent, Peripheral blood film showing normochromic normocytic anaemia with reduced reticulocyte count(<1000/ μ l) and bone marrow showing normal other cell lines with severe erythroid hypoplasia or absent erythropoiesis [5]. Secondary causes of pure red cell aplasia, including viral-induced PRCA, were reasonably excluded by Hepatitis B, C, HIV, parvo B19, cytomegalovirus and HSV screening. To exclude an autoimmune aetiology, ANA, rheumatoid factor and serum protein electrophoresis was done and a skeletal survey was performed to exclude multiple myeloma [1]. Serum LDH, ultrasonography of abdomen and CECT chest, abdomen and pelvis to exclude lymphoma, thymoma and other solid organ malignancy were also normal.

Once the clinical diagnosis of erythropoietin-induced red cell aplasia was made, it was withheld immediately and spontaneous recovery was awaited. However, the chances of recovery was remote (<2%) [5]. Red cell transfusion according to symptoms and immunosuppressive therapy with prednisolone 1mg/kg or cyclosporine A, singly or combined, are the other treatment options [1]. The recovery rate is 87% if prednisolone and cyclosporine A are used as treatment [5]. Recovery is expected to happen within three months of initiating treatment. Kidney transplantation is another option [6]. This patient was commenced on prednisolone 40mg daily along with azathioprine and haemoglobin became static and he became less transfusion dependent during follow-up.

Conclusion

The treating physician should always bear in mind the possibility of erythropoietin-induced antibody-mediated pure red cell aplasia as a possibility in a patient treated with

erythropoietin presenting with refractory anemia after ruling out other secondary causes of pure red cell aplasia. Treatment options for this rare condition include avoidance of erythropoietin, immunosuppressive therapy, and renal transplantation.

References

1. Padhi S, Behera G, Pattnaik SA, Das PK, Adhya AK, Patra S. Acquired pure red cell aplasia following recombinant erythropoietin (darbepoetin-alfa) therapy. *Indian journal of nephrology*. 2020 Mar;30(2):113. https://doi.org/10.4103/ijn.IJN_129_19
2. Lacreata G, Bucharles SG, Sevnignani G, Riella MC, Nascimento MM. Pure red cell aplasia and anti-erythropoietin antibodies in patients on hemodialysis: a report of two cases and a literature review. *Brazilian Journal of Nephrology*. 2018 Aug 23;41:145-51. <https://doi.org/10.1590/2175-8239-jbn-2018-0054>
3. Hung AK, Guy J, Behler CM, Lee EE. Anti-erythropoietin antibody associated pure red cell aplasia resolved after liver transplantation. *Case reports in transplantation*. 2015 Jul 9;2015. <https://doi.org/10.1155/2015/286276>
4. Macdougall IC. Antibody-mediated pure red cell aplasia (PRCA): epidemiology, immunogenicity and risks. *Nephrology Dialysis Transplantation*. 2005 May 1;20(suppl_4):iv9-15. <https://doi.org/10.1093/ndt/gfh1087>
5. Pollock C, Johnson DW, Hörl WH, Rossert J, Casadevall N, Schellekens H, Delage R, De Francisco A, Macdougall I, Thorpe R, Toffelmire E. Pure red cell aplasia induced by erythropoiesis-stimulating agents. *Clinical Journal of the American Society of Nephrology*. 2008 Jan 1;3(1):193-9.
6. Macdougall IC, Roger SD, De Francisco A, Goldsmith DJ, Schellekens H, Ebbers H, Jelkmann W, London G, Casadevall N, Hörl WH, Kemeny DM. Antibody-mediated pure red cell aplasia in chronic kidney disease patients receiving erythropoiesis-stimulating agents: new insights. *Kidney international*. 2012 Apr 2;81(8):727-32. <https://doi.org/10.1038/ki.2011.500>